

## Neuroprotective effects of alpha-lipoic acid on radiation-induced brainstem injury in rats

Elham Motallebzadeh<sup>1,2</sup>, Fatemeh Aghighi<sup>1</sup>, Zarichehr Vakili<sup>3</sup>, Sayyed Alireza Talaei<sup>1,\*</sup>, and Mehran Mohseni<sup>2,4,\*</sup>

<sup>1</sup>Physiology Research Center, Institute for Basic Sciences, Kashan University of Medical Sciences, Kashan, I.R. Iran.

<sup>2</sup>Anatomical Sciences Research Center, Institute for Basic Sciences, Kashan University of Medical Sciences, Kashan, I.R. Iran.

<sup>3</sup>Department of Pathology, School of Medicine, Kashan University of Medical Sciences, Kashan, I.R. Iran.

<sup>4</sup>Department of Medical Physics and Radiology, Faculty of Paramedical Sciences, Kashan University of Medical Sciences, Kashan, I.R. Iran.

### Abstract

**Background and purpose:** Alpha-lipoic acid (ALA) is an antioxidant with radioprotective properties. We designed the current work to assess the neuroprotective function of ALA in the presence of oxidative stress induced by radiation in the brainstem of rats.

**Experimental approach:** Whole-brain radiations (X-rays) was given at a single dose of 25 Gy with or without pretreatment with ALA (200 mg/kg BW). Eighty rats were categorized into four groups: vehicle control (VC), ALA, radiation-only (RAD), and radiation + ALA (RAL). The rats were given ALA intraperitoneally 1 h before radiation and killed following 6 h, thereafter superoxide dismutase (SOD), catalase (CAT), malondialdehyde (MDA), and total antioxidant capacity (TAC) in the brainstem were measured. Furthermore, a pathological examination was carried out after 24 h, 72 h, and five days to determine tissue damage.

**Findings/Results:** The findings indicated that MDA levels in the brainstem were  $46.29 \pm 1.64 \mu\text{M}$  in the RAD group and decreased in the VC group ( $31.66 \pm 1.72 \mu\text{M}$ ). ALA pretreatment reduced MDA levels while simultaneously increasing SOD and CAT activity and TAC levels ( $60.26 \pm 5.47 \text{ U/mL}$ ,  $71.73 \pm 2.88 \text{ U/mL}$ , and  $227.31 \pm 9.40 \text{ mol/L}$ , respectively). The greatest pathological changes in the rat's brainstems were seen in RAD animals compared to the VC group after 24 h, 72 h, and 5 days. As a result, karyorrhexis, pyknosis, vacuolization, and Rosenthal fibers vanished in the RAL group in three periods.

**Conclusion and implications:** ALA exhibited substantial neuroprotectivity following radiation-induced brainstem damage.

**Keywords:** Alpha-lipoic acid; Brainstem; Histopathology; Ionizing radiation; Oxidative stress.

### INTRODUCTION

While radiotherapy is an efficient treatment for brain tumors, it can damage adjacent normal tissue (1-3). Ionizing radiation is widely recognized for inducing oxidative stress in target tissues, mostly by producing reactive oxygen species (ROS) (4,5). Various macromolecules, including malondialdehyde (MDA), are made as a final product of lipid peroxidation induced by ROS (6,7).

Aerobic cells can strengthen their defense system against ROS flow by engaging in

antioxidant activities that include both enzymatic and nonenzymatic mechanisms (8). Amongst antioxidant enzymes, superoxide dismutase (SOD) catalyzes  $\text{O}_2$  reduction to  $\text{H}_2\text{O}_2$ , which is then degraded by catalase (CAT) to  $\text{H}_2\text{O}$  and  $\text{O}_2$  (9). Furthermore, prior research has shown that inflammation, vascular damage, the modified permeability of the cell membrane, and increased collagen synthesis are all important discoveries of brain tissue pathophysiology after radiation exposure (10).

#### Access this article online



Website: <http://rps.mui.ac.ir>

DOI: 10.4103/1735-5362.367798

\*Corresponding authors:

S.A. Talaei, Tel: +98-9133623240, Fax: +98-3155589336

Email: talaei@kaums.ac.ir

M. Mohseni, Tel: +98-9128957743, Fax: +98-3155540021

Email: mohseni\_me@kaums.ac.ir

Interestingly, the brainstem, located in the bottom region of the brain, is involved in essential processes such as conscious control, breathing, sleep, blood pressure, and pulse rate (11). Furthermore, the brainstem is likely connected to an increment of nausea and vomiting toxicities since the postrema inside the brainstem is recognized as the vomiting-triggering area (12).

Because free radicals largely cause radiation-induced cellular damage, compounds having direct free radical scavenging abilities are particularly intriguing as radioprotectors (13,14). The development of innovative and efficient agents to prevent radiation damage utilizing nontoxic radio-protectors is of great interest in the defense in therapy (15-17).

Alpha-lipoic acid (ALA) is an endogenously generated coenzyme that is necessary for the processes of  $\alpha$ -ketoacid dehydrogenases. Its antioxidant effects have lately been studied (18). ALA and dihydrolipoic acid, the reduced form of ALA, both quench a variety of oxygen-free radical species available in the lipid and aqueous phases, chelates transition metals, and protect membrane lipids from peroxidation and protein degradation (19). Several studies have demonstrated that ALA is a strong antioxidant with a radioprotective impact on lung damage. Moreover, it has reduced the infiltration of many inflammatory cells, fibrosis, edema, vascular and alveolar injuries (20). Furthermore, ALA maintains the antioxidant state and functional structure of the cerebellum in the entire-body X-irradiated mice (21). The purpose of this study was to study the impact of ALA on oxidative stress induced by X-rays, antioxidant state, and pathological alterations in the brainstem of rats.

## MATERIALS AND METHODS

### *Research units*

Adult male Wistar rats, weighing 180-200 g, were purchased from Kashan University of Medical Sciences' animal house, Iran. The animals were kept in standard plexiglass cages (25 (w)  $\times$  45 (L)  $\times$  20 (h) cm) with four rats per cage under the standard conditions (12/12-h light/dark, 22-24 °C, and humidity of 50-55%) throughout the investigations. All rats were fed with the standard diet food (Pars Daam Animal Food Co., Iran) and watered with no limitations.

All animal studies were conducted according to the ethical considerations and alternatives of The Ethical Committee, Deputy of Research and Technology, Kashan University of Medical Sciences. (Ethic No. IR.KAUMS.MEDNT.REC.1400.029).

### *Study design and radiation*

As per the methodology of the study, 80 rats were categorized into four groups (n = 20) utilizing a randomized block design, which included vehicle control (VC), ALA, radiation only (RAD), and radiation + ALA (RAL). The rats were moved to a facility close to the Siemens Primus linear accelerator an hour prior to the tests began (Siemens AG, Erlangen, Germany) (22). ALA (gifted by Raha Pharmaceutical Co., Isfahan, Iran) was given intraperitoneally to the ALA and RAL groups. ALA was solubilized (40 mg/mL) in 20% ethanol before dilution with distilled water. Every rat was given a 200 mg/kg solution of ALA (18) and the VC rats were treated with 20% ethanol (20,23).

The animals were anesthetized intraperitoneally an hour following the treatment by administering 60 mg/kg ketamine and 20 mg/kg xylazine (Alfasan, The Netherlands) in the prone position. The RAD and RAL rats were subsequently subjected to radiation (whole-brain) at a single dose of 25 Gy (24) with a dosage rate of 200 cGy/min in a field area of 840 cm<sup>2</sup> at a source surface distance of 100 cm (24-26). The VC group received false radiation.

### *Preparation of tissue sample*

Six hours following the rats were irradiated; they were anesthetized using intraperitoneal administrations of 20 mg/kg xylazine and 60 mg/kg ketamine (24,27). The rats' brainstem tissues were extracted (n = 5 for biochemical tests in each group). The remaining rats were killed after the anesthesia process for pathological examinations at 24 h, 72 h, and five days following radiation.

### *Biochemical analyses*

#### *Measurement of MDA*

According to the producer's instructions, the enzyme-linked immunosorbent assay (ELISA) technique was carried out to evaluate the amount of MDA activity (Zell Bio, Germany).

**Measurement of antioxidant markers**

According to the producer's protocol, the ELISA technique was utilized to measure the amount of CAT, SOD, and total antioxidant capacity (TAC) activity (Zell Bio, Germany).

**Histopathological study**

The samples underwent 48 h of fixation process using 10% neutral buffered formalin and then a dehydration procedure utilizing a serial dilution (70, 90, and 100%) of graded ethanol. Following that, the specimens were embedded in paraffin wax. Then, slices were serially cut at a thickness of 5 µm, stained with hematoxylin and eosin (H&E), and examined under a light microscope (28).

**Statistical analysis**

The data were reported as mean ± SD. The normality of the data was checked using the Shapiro-Wilk test, and then analyzed using one-way ANOVA followed by Tukey's posthoc test. *P*-values < 0.05 were considered significant.

**RESULTS**

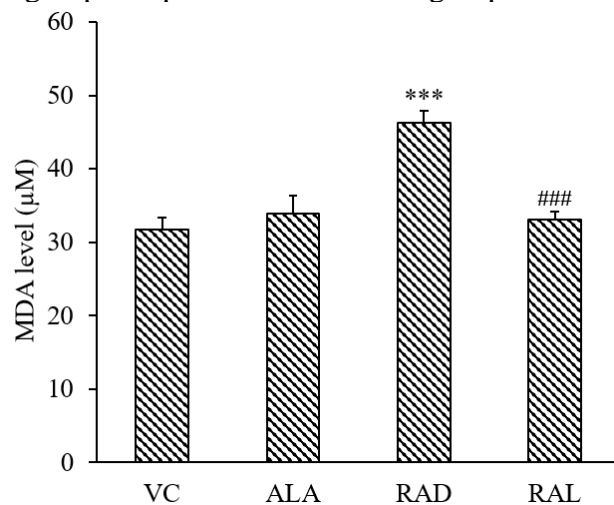
**The effects of ALA on the biomarkers of oxidative stress**

MDA concentrations in brainstem tissue homogenate were measured for six h following radiation. MDA levels in brainstem tissue were considerably greater in the RAD group (46.29 ± 1.64 µM) than in the VC group (31.66 ± 1.72 µM). MDA levels were considerably reduced (33.04 ± 1.16 µM) after

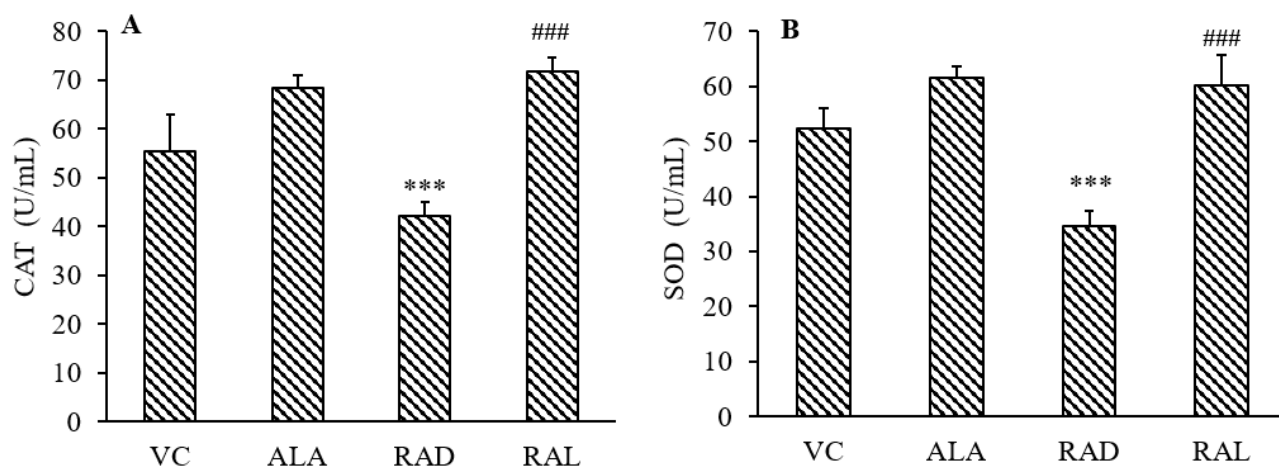
pretreatment with 200 mg/kg ALA. Furthermore, there was no statistically meaningful difference in MDA levels between the ALA and VC groups (Fig. 1).

**The effects of ALA on the antioxidant biomarkers**

Figure 2 depicts the impacts of ALA on the activity of SOD and CAT in all examined groups. The antioxidants CAT and SOD activity were significantly reduced in the irradiated rats (RAD) compared with the VC group. Figure 2 shows that CAT and SOD activity was substantially higher in the RAL group compared with the RAD group.



**Fig. 1.** The MDA levels (µM) in the brainstem tissues of rats in various research groups (n = 5 in each group). The data are provided as mean ± SD. \*\*\**P* < 0.001 indicates significant differences compared to VC; and ###*P* < 0.001 versus RAD group. MDA, Malondialdehyde; VC, vehicle control; ALA, alpha-lipoic acid; RAD, radiation-only; RAL, radiation + ALA.



**Fig. 2.** Enzyme activities of (A) CAT and (B) SOD in the brainstem tissues of rats in various study groups (n = 5 for each). Data are shown as mean ± SD. \*\*\**P* < 0.001 indicates significant differences compared to VC; and ###*P* < 0.001 versus RAD group. CAT, Catalase; SOD, superoxide dismutase; VC, vehicle control; ALA, alpha-lipoic acid; RAD, radiation-only; RAL, radiation + ALA.

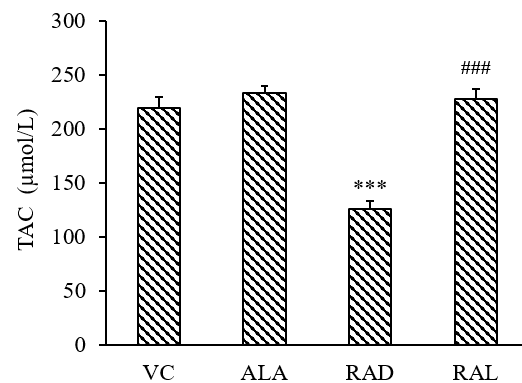
### The effects of ALA on the total antioxidant capacity

Figure 3 indicates TAC activity in brainstem tissues was at lower levels in the RAD group ( $125.98 \pm 7.27$  mol/L) in comparison with the VC group ( $219.24 \pm 10.36$  mol/L). Furthermore, pretreatment with 200 mg/kg ALA substantially increased TAC activity in the rats' brainstems ( $227.31 \pm 9.40$  mol/L). The level of TAC, however, did not change significantly between the VC and ALA groups ( $232.78 \pm 7.02$  mol/L).

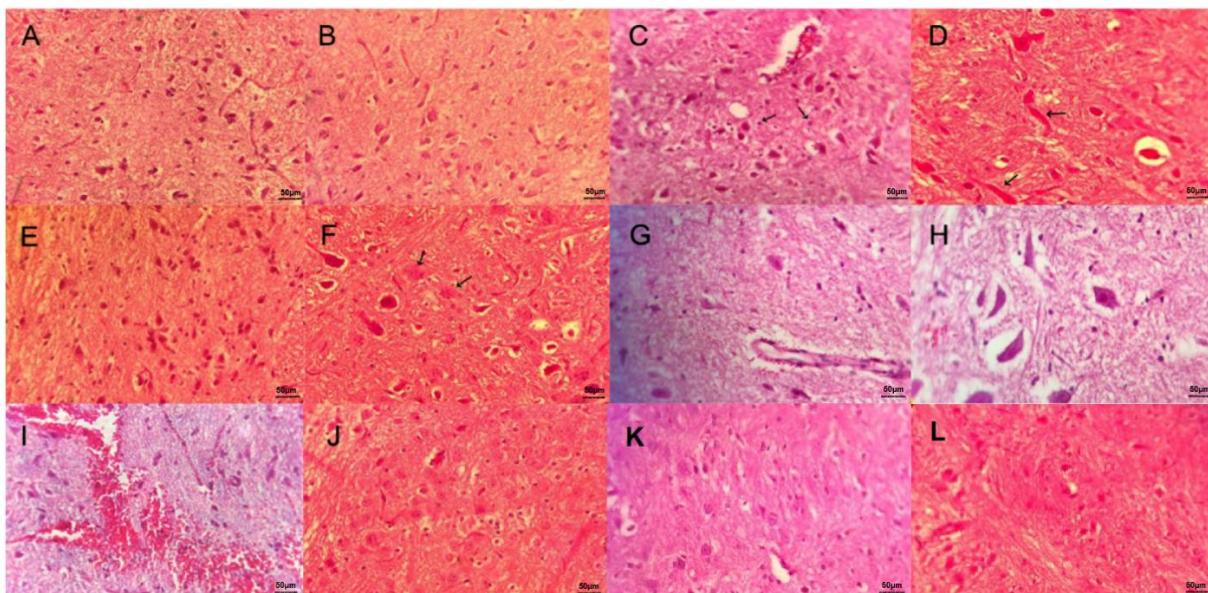
### The effects of ALA on the histopathology of the rats' brainstem

Figure 4 depicts an evaluation of H&E-stained slices from control rats that indicated no pathologic alterations (panel A). Polymorphic and pyramidal cells were seen in the brainstem of control rats. Those that received ALA (panel B) had a normal histological pattern as well. Many degenerative abnormalities were detected in the RAD rats' brainstems. There was no sign of polymorphic cells. As a result, polymorphic cells might be more susceptible to radiation compared with pyramidal ones. Congestion and pyknosis were observed on photomicrographs of the brainstems of the irradiated rats (panel C). In addition, microglial nodules and Rosenthal fibers were seen 24 h following radiation (panels D and E). Karyorrhexis was observed 72 h following

radiation (panel F). Furthermore, Rosenthal fibers and microglial nodules were seen in the brainstem. Following five days, the cell population in the tissue was reduced (panel G). Following five days, the next panels showed hyperemia and vacuolization (panels H and I). Inflammation, congestion, and pyknosis were diagnosed at the entire time points following radiation. Notable pathological alterations such as karyorrhexis, pyknosis, Rosenthal fibers, and vacuolization vanished in the RAL group after three-time points (panels J, K, and L).



**Fig. 3.** TAC activity in the rats' brainstems in various study groups ( $n = 5$  for each). Data are shown as mean  $\pm$  SD. \*\*\* $P < 0.001$  indicates significant differences compared to VC; and ### $P < 0.001$  versus RAD group. TCA, Total antioxidant capacity; VC, vehicle control; ALA, alpha-lipoic acid; RAD, radiation-only; RAL, radiation + ALA.



**Fig. 4.** A photomicrograph of the slices, stained with hematoxylin and eosin, of (A) the VC rats' brains illustrates a normal histological pattern of the brainstem, polymorphic, and pyramidal cells; (B) brains of ALA-administered rats indicate a normal structure of the brainstem; (C) the rats' brainstems following 24-h irradiation indicate (C) nuclear pyknosis (arrows), (D) Rosenthal fibers (arrows), and (E) microglial nodules; (F) the rats' brainstems following 72-h irradiation illustrate karyorrhexis (arrows); the rats' brainstems following 5-day irradiation indicate (G) reduced cell populations, (H) vacuolization; and (I) hyperemia; the rats' brainstems that were protected with alpha-lipoic acid indicates a normal histological pattern that contains polymorphic cells following (J) 24-h, (K) 72-h, and (L) 5-day irradiation. Magnification:  $\times 400$ .

## DISCUSSION

There exists a lot of interest in finding and producing non-toxic radioprotective chemicals. An effective radioprotector might be useful in therapeutic settings that employ ionizing radiation. The major findings of our study verified ALA's radioprotective properties in the brainstem of radiated (whole-brain) rats (29). The findings of this study also showed that ALA effectively alleviates morphological degenerations induced by radiation and influences oxidative stress as well as antioxidant elements.

Numerous researches have been conducted to analyze the protective impact of ALA on normal tissue cells (19-21,30). Nonetheless, to our best knowledge, this *in vivo* study is the first try to explore the protecting properties of ALA toward the degenerative impacts of X-rays on the brainstems of rats. ALA is a powerful antioxidant that eliminates free radicals by recycling alpha-tocopherol and ascorbic acid (31). Various investigations have indicated that ALA may have radioprotective properties in some murine organs, including the thyroid and intestine (32,33). Radiotherapy degenerates cells and tissues through DNA interaction or the production of harmful free radicals. Nevertheless, free radicals are responsible for above two-thirds of the degenerative properties (34). MDA levels rise when ROS interacts with the unsaturated forms of membrane free-fatty acids, indicating lipid peroxidation activity. The anti-lipid peroxidation (radiation-induced) activity of ALA is owing to its free-radical scavenging abilities (35-37). Our research results are in agreement with the findings in the brain tissues, shown by Manda *et al.* which demonstrated that the protective properties of ALA pretreatment regarding MDA content were greatest in the brain when compared to other tissues, including the testis, kidney, spleen, as well as the liver (19). According to previous researches, ALA is extremely efficient in protecting against lipid peroxidation induced by stress (38,39).

Moreover, the whole-brain X-raying of rats reduced CAT and SOD activity in brainstem tissues, most likely due to oxidative enzyme

inactivation leading to increased ROS generation (2,40). Nevertheless, the ALA treatment of rats led to a rise in antioxidant enzyme activity and a reduction in lipid peroxidation (30). Notably, Said *et al.* demonstrated ALA's antioxidant ability through restored levels of GSH and CAT activity, as well as preventing the lipid peroxidation process in radiation-exposed animals treated with ALA compared with those that were not received ALA (41). As a result, the level of TAC in the rats' brainstem tissues was substantially greater in the RAL group than in the RAD group. Accordingly, Manda *et al.* demonstrated that TAC plasma levels in ALA pretreatment groups were considerably greater than in their equivalent VC groups within cerebellum tissue (21).

Histopathological investigations revealed that the brainstems of the VC and ALA groups show a normal histological pattern, including polymorphic and pyramid cells, which is consistent with our biochemical test results. Alpha-lipoic acid can neutralize free radicals directly and has been shown to reduce radiation-induced oxidative stress (21). Given that ionizing radiation induces oxidative stress via the generation of reactive oxygen species (ROS) and free radicals in irradiated tissue (23). We expected that according to the results of previous studies on other organs (18), the treatment group alone did not have any pathological changes. According to our expectations, no harmful effect of ALA was seen in brainstem tissue either. Rosenthal fibers and microglial nodules were found in photomicrographs of the irradiated rats' brainstems 24 and 72 h following radiation. However, karyorrhexis was only observed 72 h following radiation. The tissues showed reduced cell population, hyperemia, and vacuolization following five days. Furthermore, inflammation, congestion, and pyknosis were observed at all time periods. Previously, histopathological alterations in the brain of rats exposed to  $\gamma$ -radiation were studied, including pyknosis, vacuolization, as well as focal gliosis (42). Also, pathological alterations, including microglial and inflammatory reactions, were found in the brain

tissue of the rats following a dose of 20 Gy administered to the entire brain (43). Our findings are aligned with the findings indicated by Manda *et al.* They found that ALA treatment decreases or eliminates a variety of pathological abnormalities in cerebellum-irradiated mice, including Purkinje cell migration, vacuolation, and necrosis (21,44). Polymorphic cells, contrary to pyramid cells, were not seen in the irradiated groups, possibly attributed to their susceptibility to radiation. At three time points, before radiation, ALA treatment eliminated part of the damage induced by radiation within the brainstem, such as karyorrhexis, pyknosis, vacuolization, and Rosenthal fibers.

### CONCLUSION

Overall, our data suggest that ALA may have a neuroprotective activity against oxidative stress induced by radiation and pathological modifications in the brainstems of rats. As a result, using this drug may allow patients to be exposed to greater radiation doses during radiotherapy, improving their life quality and therapeutic ratios. Nonetheless, additional clinical and experimental research is needed to reach a reliable conclusion in this respect.

### Acknowledgments

This study was financially supported by the Deputy of Research and Technology, Kashan University of Medical Sciences, Kashan, Iran through Grant No. 99253.

### Conflict of interest statement

The authors declared no conflict of interest in this study.

### Authors' contribution

S.A. Talaei, E. Motallebzadeh, and M. Mohseni designed the study. M. Mohseni, F. Aghighi, and Z. Vakili performed all the experiments and collected the data. S.A. Talaei, E. Motallebzadeh, and Z. Vakili analyzed and interpreted the data. E. Motallebzadeh and S.A. Talaei drafted the manuscript. All the authors read and approved the final version of the manuscript.

### REFERENCES

1. Caceres LG, Bertolino LA, Saraceno GE, Zubilete MAZ, Uran SL, Capani F, *et al.* Hippocampal-related memory deficits and histological damage induced by neonatal ionizing radiation exposure. Role of oxidative status. *Brain Res.* 2010;1312:67-78. DOI: 10.1016/j.brainres.2009.11.053.
2. Motallebzadeh E, Azami Tameh A, Zavareh SAT, Farhood B, Aliasgharzedeh A, Mohseni M. Neuroprotective effect of melatonin on radiation-induced oxidative stress and apoptosis in the brainstem of rats. *J Cell Physiol.* 2020;235(11):8791-8798. DOI: 10.1002/jcp.29722.
3. Sezen O, Ertekin MV, Demircan B, Karshoğlu İ, Erdoğan F, Koçer İ, *et al.* Vitamin E and L-carnitine, separately or in combination, in the prevention of radiation-induced brain and retinal damages. *Neurosurg Rev.* 2008;31(2):205-213. DOI: 10.1007/s10143-007-0118-0.
4. Nuzkiewicz J, Woźniak A, Szewczyk-Golec K. Ionizing radiation as a source of oxidative stress-the protective role of melatonin and vitamin D. *Int J Mol Sci.* 2020;21(16):5804,1-22. DOI: 10.3390/ijms21165804.
5. Sathyaikumar K, Swapna I, Reddy P, Murthy CR, Gupta AD, Senthilkumaran B, *et al.* Fulminant hepatic failure in rats induces oxidative stress differentially in cerebral cortex, cerebellum and pons medulla. *Neurochem Res.* 2007;32(3):517-524. DOI: 10.1007/s11064-006-9265-x.
6. Sharma S, Haldar C. Melatonin prevents X-ray irradiation induced oxidative damage in peripheral blood and spleen of the seasonally breeding rodent, *Funambulus pennanti* during reproductively active phase. *Int J Radiat Biol.* 2006;82(6):411-419. DOI: 10.1080/09553000600774105.
7. Taysi S, Polat F, Gul M, Sari R, Bakan E. Lipid peroxidation, some extracellular antioxidants, and antioxidant enzymes in serum of patients with rheumatoid arthritis. *Rheumatol Int.* 2002;21(5):200-204. DOI: 10.1007/s00296-001-0163-x.
8. Mousavi SH, Bakhtiari E, Hosseini A, Jamialahmadi K. Protective effects of glucosamine and its acetylated derivative on serum/glucose deprivation-induced PC12 cells death: role of reactive oxygen species. *Res Pharm Sci.* 2018;13(2):121-129. DOI: 10.4103/1735-5362.223794.
9. Shaban NZ, Zahran AMA, El-Rashidy FH, Kodous ASA. Protective role of hesperidin against  $\gamma$ -radiation-induced oxidative stress and apoptosis in rat testis. *J Biol Res (Thessalon).* 2017;24(1):1-11. DOI: 10.1186/s40709-017-0059-x.
10. Erol FS, Topsakal C, Ozveren MF, Kaplan M, Ilhan N, Ozercan IH, *et al.* Protective effects of melatonin and vitamin E in brain damage due to gamma radiation: an experimental study. *Neurosurg Rev.* 2004;27(1):65-69. DOI: 10.1007/s10143-003-0291-8.



11. Fernandez-Gil MA, Palacios-Bote R, Leo-Barahona M, Mora-Encinas J, editors. Anatomy of the brainstem: a gaze into the stem of life. *Semin Ultrasound CT and MR*. 2010;31(3):196-219. DOI: 10.1053/j.sult.2010.03.006.
12. Schiller K, Specht HM, Haller B, Hallqvist D, Devecka M, von Rose AB, et al. Correlation between delivered radiation doses to the brainstem or vestibular organ and nausea & vomiting toxicity in patients with head and neck cancers-an observational clinical trial. *Radiat Oncol*. 2017;12(1):113. DOI: 10.1186/s13014-017-0846-4.
13. Karbownik M, Reiter RJ. Antioxidative effects of melatonin in protection against cellular damage caused by ionizing radiation. *Proc Soc Exp Biol Med*. 2000;225(1):9-22. DOI: 10.1046/j.1525-1373.2000.22502.x.
14. Reiter RJ, Tan DX, Herman TS, Thomas Jr CR. Melatonin as a radioprotective agent: a review. *Int J Radiat Oncol Biol Phys*. 2004;59(3):639-653. DOI: 10.1016/j.ijrobp.2004.02.006.
15. Jafarpour SM, Safaei M, Mohseni M, Salimian M, Aliasgharzadeh A, Fahood B. The radioprotective effects of curcumin and trehalose against genetic damage caused by I-131. *Indian J Nucl Med*. 2018;33(2):99-104. DOI: 10.4103/ijnm.IJNM\_158\_17.
16. Li J, Meng Z, Zhang G, Xing Y, Feng L, Fan S, et al. N-acetylcysteine relieves oxidative stress and protects hippocampus of rat from radiation-induced apoptosis by inhibiting caspase-3. *Biom Pharmacother*. 2015;70:1-6. DOI: 10.1016/j.biopha.2014.12.029.
17. Sudjarwo SA, Sudjarwo GW. Protective effect of curcumin on lead acetate-induced testicular toxicity in Wistar rats. *Res Pharmaceut Sci*. 2017;12(5):381-390. DOI: 10.4103/1735-5362.213983.
18. Bilska A, Wlodek L. Lipoic acid-the drug of the future? *Pharmacol Rep*. 2005;57(5):570-577. PMID: 16227639.
19. Manda K, Ueno M, Moritake T, Anzai K.  $\alpha$ -Lipoic acid attenuates x-irradiation-induced oxidative stress in mice. *Cell Biol Toxicol*. 2007;23(2):129-137. DOI: 10.1007/s10565-006-0137-6.
20. Azmoonfar R, Amini P, Yahyapour R, Rezaeyan A, Tavassoli A, Motevaseli E, et al. Mitigation of radiation-induced pneumonitis and lung fibrosis using alpha-lipoic acid and resveratrol. *Antiinflamm Antiallergy Agents Med Chem*. 2020;19(2):149-157. DOI: 10.2174/1871523018666190319144020.
21. Manda K, Ueno M, Moritake T, Anzai K. Radiation-induced cognitive dysfunction and cerebellar oxidative stress in mice: protective effect of  $\alpha$ -lipoic acid. *Behavi Brain Res*. 2007;177(1):7-14. DOI: 10.1016/j.bbr.2006.11.013.
22. Li J, Zhang G, Meng Z, Wang L, Liu H, Liu Q, et al. Neuroprotective effect of acute melatonin treatment on hippocampal neurons against irradiation by inhibition of caspase-3. *Exp Ther Med*. 2016;11(6):2385-2390. DOI: 10.3892/etm.2016.3215.
23. Yahyapour R, Amini P, Saffar H, Motevaseli E, Farhood B, Pooladvand V, et al. Protective effect of metformin, resveratrol and alpha-lipoic acid on radiation-induced pneumonitis and fibrosis: a histopathological study. *Curr Drug Res Rev*. 2019;11(2):111-117. DOI: 10.2174/2589977511666191018180758.
24. Naseri S, Moghahi SMHN, Mokhtari T, Roghani M, Shirazi AR, Malek F, et al. Radio-protective effects of melatonin on subventricular zone in irradiated rat: decrease in apoptosis and upregulation of nestin. *J Mol Neurosci*. 2017;63(2):198-205. DOI: 10.1007/s12031-017-0970-5.
25. Mohseni M, Mihandoost E, Shirazi A, Sepehrizadeh Z, Bazzaz JT, Ghazi-khansari M. Melatonin may play a role in modulation of bax and bcl-2 expression levels to protect rat peripheral blood lymphocytes from gamma irradiation-induced apoptosis. *Mutat Res*. 2012;738-739:19-27. DOI: 10.1016/j.mrfmmm.2012.08.006.
26. Panagiotakos G, Alshamy G, Chan B, Abrams R, Greenberg E, Saxena A, et al. Long-term impact of radiation on the stem cell and oligodendrocyte precursors in the brain. *PloS One*. 2007;2(7):e588. DOI: 10.1371/journal.pone.0000588.
27. Ferrer I, Serrano T, Rivera R, Olive M, Zujar M, Graus F. Radiosensitive populations and recovery in X-ray-induced apoptosis in the developing cerebellum. *Acta Neuropathol*. 1993;86(5):491-500. DOI: 10.1007/BF00228585.
28. Wang P, Han J, Wei M, Xu Y, Zhang G, Zhang H, et al. Remodeling of dermal collagen in photoaged skin using low-dose 5-aminolevulinic acid photodynamic therapy occurs via the transforming growth factor- $\beta$  pathway. *J Biophotonics*. 2018;11(6):e201700357. DOI: 10.1002/jbio.201700357.
29. Kopjar N, Miočić S, Ramić S, Milić M, Viculin T. Assessment of the radioprotective effects of amifostine and melatonin on human lymphocytes irradiated with gamma-rays *in vitro*. *Arh Hig Rada Toksikol*. 2006;57(2):155-163. PMID: 16832970.
30. El-Dein E, Anees LM, Aly SME. Effects of  $\alpha$ -lipoic acid on  $\gamma$ -radiation and lindane-induced heart toxicity in rats. *Pakistan J Zool*. 2016;48(5):1523-1529.
31. Shay KP, Moreau RF, Smith EJ, Smith AR, Hagen TM. Alpha-lipoic acid as a dietary supplement: molecular mechanisms and therapeutic potential. *Biochim Biophys Acta*. 2009;1790(10):1149-1160. DOI: 10.1016/j.bbagen.2009.07.026
32. Jeong BK, Song JH, Jeong H, Choi HS, Jung JH, Hahm JR, et al. Effect of alpha-lipoic acid on radiation-induced small intestine injury in mice. *Oncotarget*. 2016;7(12):15105-15117. DOI: 10.18632/oncotarget.7874.
33. Jung JH, Jung J, Kim SK, Woo SH, Kang KM, Jeong BK, et al. Alpha lipoic acid attenuates radiation-induced thyroid injury in rats. *PLoS One*. 2014;9(11):e112253. DOI: 10.1371/journal.pone.0112253.

34. Seker U, Aktas A, Nergiz Y, Zincircioglu S, Ketani M. Investigation of the protective effects of melatonin, amifostine (WR-2721), and N-acetylcysteine on radiotherapy-induced uterine tissue injury in rats. *Int J Radiat Res.* 2020;18(4):791-798. DOI: 10.52547/ijrr.18.4.791.
35. Di Stefano A, Sozio P, Cocco A, Iannitelli A, Santucci E, Costa M, *et al.* L-Dopa and Dopamine-(R)- $\alpha$ -lipoic acid conjugates as multifunctional codrugs with antioxidant properties. *J Med Chem.* 2006;49(4):1486-1493. DOI: 10.1021/jm051145p.
36. Perricone N, Nagy K, Horváth F, Dajkó G, Uray I, Nagy IZ. Alpha lipoic acid (ALA) protects proteins against the hydroxyl free radical-induced alterations: rationale for its geriatric topical application. *Arch Gerontol Geriatr.* 1999;29(1):45-56. DOI: 10.1016/s0167-4943(99)00022-9.
37. Wollin SD, Jones PJ.  $\alpha$ -Lipoic acid and cardiovascular disease. *J Nutr.* 2003;133(11):3327-3330. DOI: 10.1093/jn/133.11.3327.
38. Arivazhagan P, Thilakavathy T, Panneerselvam C. Antioxidant lipoate and tissue antioxidants in aged rats. *J Nutr Biochem.* 2000;11(3):122-127. DOI: 10.1016/S0955-2863(99)00079-0.
39. Şahin M, Sağdıç G, Elmas O, Akpınar D, Derin N, Aslan M, *et al.* Effect of chronic restraint stress and alpha-lipoic acid on lipid peroxidation and antioxidant enzyme activities in rat peripheral organs. *Pharmacol Res.* 2006;54(3):247-252. DOI: 10.1016/j.phrs.2006.05.007.
40. Mihandoost E, Shirazi A, Mahdavi SR, Aliasgharzadeh A. Consequences of lethal-whole-body gamma radiation and possible ameliorative role of melatonin. *Sci World J.* 2014;2014:621570. DOI: 10.1155/2014/621570.
41. Said RS, Mohamed HA, Kassem DH. Alpha-lipoic acid effectively attenuates ionizing radiation-mediated testicular dysfunction in rats: Crosstalk of NF- $\kappa$ B, TGF- $\beta$ , and PPAR- $\gamma$  pathways. *Toxicology.* 2020;442:152536. DOI: 10.1016/j.tox.2020.152536.
42. El-Maraghi EF, Abdel-Fattah KI, Soliman SM, El-Sayed WM. Taurine provides a time-dependent amelioration of the brain damage induced by  $\gamma$ -irradiation in rats. *J Hazard Mater.* 2018; 359:40-46. DOI: 10.1016/j.jhazmat.2018.07.005.
43. Kale A, Pişkin Ö, Baş Y, Aydın BG, Can M, Elmas Ö, *et al.* Neuroprotective effects of quercetin on radiation-induced brain injury in rats. *J Radiat Res.* 2018;59(4):404-410. DOI: 10.1093/jrr/rry032.
44. Sheikholeslami S, Khodaverdian S, Dorri-Giv M, Hosseini SM, Souri S, Abedi-Firouzjah R, *et al.* The radioprotective effects of alpha-lipoic acid on radiotherapy-induced toxicities: a systematic review. *Int Immunopharmacol.* 2021;96:107741. DOI: 10.1016/j.intimp.2021.107741.