



Further evidence to support acute and chronic anti-inflammatory effects of *Nasturtium officinale*

Mostafa Mostafazadeh^{1,2}, Heibatollah Sadeghi^{3,4}, Hossein Sadeghi^{3,5,*}, Vahid Zarezade⁶, Abolghasem Hadinia⁴, and Esmaeel Panahi Kokhdan³

¹Department of Biochemistry and Clinical Laboratories, Tabriz University of Medical Sciences, Tabriz, I.R. Iran.

²Students' Research Committee, Tabriz University of Medical Sciences, Tabriz, I.R. Iran.

³Medicinal Plants Research Center, Yasuj University of Medical Sciences, Yasuj, I.R. Iran.

⁴Cellular and Molecular Research Center, Yasuj University of Medical Sciences, Yasuj, I.R. Iran.

⁵Department of Pharmacology, Faculty of Medicine, Yasuj University of Medical Sciences, Yasuj, I.R. Iran.

⁶Department of Clinical Biochemistry, Faculty of Medicine, Behbahan University of Medical Sciences, Behbahan, I.R. Iran.

Abstract

Background and purpose: Previously, we reported the anti-inflammatory properties of *Nasturtium officinale* (watercress) in several models of acute inflammation. This study was designed to explore the effects of topical and systemic administrations of *N. officinale* in the two chronic inflammatory models and to evaluate the role of TNF- α and IL-1 β in these effects.

Experimental approach: Folin-Ciocalteu and aluminum chloride methods were used to estimate the extract's total phenol and flavonoid content, respectively. Carrageenan-induced paw edema was carried out and TNF- α and IL-1 β concentrations in the carrageenan-treated paw tissue were determined. Formalin injection into rat hind paws (7 days) and the application of 12-O-tetradecanoyl phorbol-13-acetate (TPA) on mouse ears (9 days) were used to simulate chronic inflammation. Furthermore, a histological assessment of the inflamed tissues was carried out.

Findings/Results: The extract's flavonoid and phenolic contents were 90.26 ± 4.81 mg rutin equivalents/g and 68 ± 8.16 gallic acid equivalents/g gallic acid, respectively. *N. officinale* pretreatment in all doses administered considerably decreased carrageenan-induced edema. The extract also reduced IL-1 β levels in carrageenan-treated paws while did not affect TNF- α levels. Oral and topical administrations of *N. officinale* considerably reserved the paw and ear edema. The extract also ameliorated the tissue injuries due to formalin and TPA challenges.

Conclusion and implications: The data confirmed the topical and systemic anti-inflammatory effects of watercress against two chronic models of inflammation. They suggested that these properties are not related to TNF- α but could be attributed to inhibition of IL-1 β and inhibition of leukocyte infiltration.

Keywords: Anti-inflammatory; Interleukin-1 beta; *Nasturtium officinale*; Tetradecanoyl phorbol acetate; Tumor necrosis factor-alpha.

INTRODUCTION

Herbal medicines have long been used for therapeutic goals and beneficial effects in different ailments (1). Cruciferous vegetables, particularly cauliflower, cabbage, broccoli, and watercress are broadly eaten worldwide. They contain soluble fiber, multiple nutrients, and vitamin C (2).

Nasturtium officinale R. Br. (watercress), which belongs to the Brassicaceae family, is found in most regions (native to Europe).

Access this article online



Website: <http://rps.mui.ac.ir>

DOI: 10.4103/1735-5362.343084

*Correspondence author: H. Sadeghi
Tel: +98-7413346070, Fax: +98-7413346071
Email: h_sadeghi_m@yahoo.com, hossein.sadeghi@yums.ac.ir

Aerial parts of the watercress are usually eaten as a vegetable in salads and different recipes. Watercress is considered an important food supplementation for preventing cancer and related diseases, especially breast cancer risk (3). Other health benefits of watercress can be mentioned including asthma, hypertension, renal colic, and diabetes (4). Several studies have confirmed the antioxidant effects of watercress in vivo and in vitro conditions (5,6). Furthermore, the plant is famous for possessing numerous pharmacological properties such as anti-hyperlipidemic, hypoglycemic (7), anti-ulcerogenic (8), hepatoprotective (9), nephroprotective (10), anticarcinogenic (11), anti-fibrotic (12), and appetite stimulator (13). It has also been reported that crude watercress extract improved oxymetholone-induced toxicity in mouse testis *via* antioxidant pathways (14). Previously, we have documented the anti-inflammatory properties of *N. officinale* ethanolic extract in some acute animal models of inflammations (15).

The nuclear factor kappa B (NF- κ B) is a family of transcription factors that plays a crucial role in developing immune response. The cytokines of the tumor necrosis factor (TNF) family and interleukin (IL)-1 β facilitate the synthesis of genes that regulate inflammation, proliferation, and differentiation, mainly through the NF- κ B pathway (16,17). Furthermore, the earlier study also revealed that watercress extract inhibited croton oil-induced ear edema through NF- κ B and glucocorticoid receptor pathways without producing important signs of toxicity (18). In addition, there are some reports on the vital role of cytokines (IL- β and TNF- α) in some diseases, including dyslipidemia and inflammation (19).

Hence, the main objective of the current research was to explore the systemic and topical anti-inflammatory actions of *N. officinale* against two models of chronic inflammation and the role of IL- β and TNF- α , as proinflammatory cytokines, in these effects.

MATERIALS AND METHODS

Plant material

The raw materials of watercress were harvested from the area around Yasuj, Iran,

which was recognized by Dr. A. Jafari (University of Yasuj, Iran), and stored there in the herbarium under voucher No. HYU30230. The collected plant was dried in the shade and then powdered.

Chemicals

Carrageenan and formaldehyde were obtained from Fluka Chemical (Switzerland) and Merck Co. (Darmstadt, Germany). TPA and indomethacin, phenylmethylsulfonyl fluoride, bovine serum albumin, aprotinin A, ethylenediaminetetraacetic acid (EDTA), benzethonium chloride, and Tween[®] 20 were obtained from Sigma-Aldrich Chemical Company (St. Louis, MO, USA). IL-1 β and TNF- α enzyme-linked immunosorbent assay (ELISA) kits were obtained from ALPCO, USA, and R&D Company, respectively.

Preparation of the extract

The pulverized aerial parts of the watercress were extracted two times with ethanol:water (7:3) at the laboratory temperature (25 °C) for 48 h. Next, the organic solvent was evaporated using a rotary evaporator (60 °C) to obtain a concentrated extract. Then, the viscous material was dried and stored at 4 °C for further studies.

Experimental animals

Swiss albino male mice (25-35 g) and Wistar male rats (200-250 g) were obtained from the Pasteur Institute of Iran, Tehran. Animals were kept at room temperature (24 \pm 2 °C, 12/12 h light/dark cycle) and had free access to a standard pellet diet and water *ad libitum*. This work was performed and approved by Yasuj University of Medical Sciences, Iran, following international standards for the care and use of experimental animals (Ethical No. 193.165).

Evaluation of total phenol

The Folin-Ciocalteu process was used to estimate the content of the total phenol of the extract (20). Folin-Ciocalteu reagent (0.5 mL), watercress extract (0.1 mL, 1 mg/mL), and 0.4 mL of sodium carbonate 7.5% were mixed. After 30 min retention in lab temperature, the absorption of the mixture was read at 756 nm. According to the standard curve, total phenol content was estimated and represented as gallic acid equivalents per gram of the dried extract.

Evaluation of total flavonoid

The aluminum chloride method was used to estimate the total content of flavonoids (21). Sodium nitrate (5%), aluminum chloride solution (10%) and 0.1 mL of the extract (1 mg/mL) were mixed and incubated for 5 min in a dark place. Then, NaOH (0.5 mL, 1 M) was added. Next, the absorbance of the solution was recorded in triplicate at 510 nm. According to the standard curve, the total flavonoid content was determined, and the data was represented as mg rutin equivalent per gram of the dried extract.

Carrageenan-induced paw edema in rats

The acute inflammatory model of subplantar injection of carrageenan in rats was used (22,23). Carrageenan suspension in normal saline (100 μ L of a 1% (w/v)) was injected into the rat's hind paw to induce edema. Oral treatment of normal saline, indomethacin (10 mg/kg), and *N. officinale* extract (250, 500, and 750 mg/kg) were given 45 min before the carrageenan challenge (15). We recorded paw thickness 4 h after carrageenan injection to confirm the induction of inflammation. Lastly, the rats were euthanized, and the inflamed paws were harvested to determine the IL-1 β and TNF- α levels.

Formalin-induced chronic inflammation

The Wistar rat was randomly classified into three groups (six each), including arthritic group, subplantar injection of formaldehyde (0.1 mL of 2% formalin in normal saline) was done on days one and three of the experiment, the animals also received saline (10 mL/kg/day, p.o.) daily for 6 days; arthritic group + indomethacin, subplantar injection of formaldehyde (0.1 mL of 2% formalin in normal saline) was done on days one and three of the experiment, the animals also received indomethacin (10 mL/kg/day, p.o.) daily for 6 days; arthritic group + *N. officinale* extract, subplantar injection of formaldehyde (0.1 mL of 2% formalin in normal saline) was done on days one and three of the experiment, rats were given the extract (500 mg/kg/day, p.o.) daily for 6 days. Formaldehyde was injected 45 min after drug administration (24). Paw thickness was measured immediately before formalin, then on

days 1, 2, 3, 4, 5, 6, and 7 using a digital caliper (Mitutoyo, Japan). Animals were euthanized on the seventh day, and the formaldehyde-treated paws were collected and fixed in formalin 10% for pathological evaluation.

TPA-induced chronic skin inflammation

Multiple topical administration of TPA was used to induce chronic skin inflammation as defined by Stanley et al. (25). On-ear mice applied topical administration of 20 μ L of TPA (2.5 μ g/ear in acetone \times 5, nine days on alternate days) to induce chronic inflammation (25). Normal saline, dexamethasone (0.5 mg/ear), and *N. officinale* extract (5 mg/ear) were also topically applied twice a day for 9 consecutive days, in the morning (9 AM) and 6 h later (3 PM). Animals' treatment was performed on the last day only in the morning. Six h after the last treatment, the animals were euthanized and both their ears were punched (6 mm diameter), weighed, and kept in formalin 10% for more studies.

Assessment of the TNF- α and IL-1 β concentration in the carrageenan-treated rat paws

The concentration of TNF- α and IL-1 β in the carrageenan-injected paws was measured as mentioned earlier, using ELISA (24,26). The collected paw tissue was weighed and saved in liquid nitrogen (-70 $^{\circ}$ C). Briefly, the collected samples were homogenized in the saline phosphate buffer (PBS; pH = 7.4) containing 10 mM EDTA, 0.5% bovine serum albumin, apportioning A 20 KI 0.1 mM phenylmethylsulfonyl fluoride, 0.4 M NaCl, 0.05% Tween[®] 20, and 0.1 mM benzethonium chloride. The mixture was centrifuged at 12,000 g for 60 min at 4 $^{\circ}$ C. Finally, the supernatant was collected and analyzed for the concentration of IL-1 β and TNF- α by ELISA.

Pathological examination

Three samples of TPA-treated ears and formalin-treated paw from each group were amputated and stored in a 10% formalin. After 7 days, the fixed samples were embedded in paraffin, sliced into 3-4 μ m pieces, and were stained with eosin and hematoxylin (H&E) for assessment in a blinded manner.

Statistical evaluation

The data are expressed as means \pm SEM and were analyzed with One-way ANOVA followed by Tukey's post hoc test (SPSS 18.0). The difference at $P < 0.05$ was considered statistically significant.

RESULTS

Total flavonoid and phenolic content

The flavonoid and phenolic contents of *N. officinale* extract were found to be 90.26 ± 4.81 mg rutin equivalents/g dry weight in the extract and 68 ± 8.16 mg gallic acid equivalents/g dry weight in the extract, respectively.

Carrageenan-induced rat paw edema

As depicted in Fig. 1, intraplantar injection of carrageenan-induced a significant paw

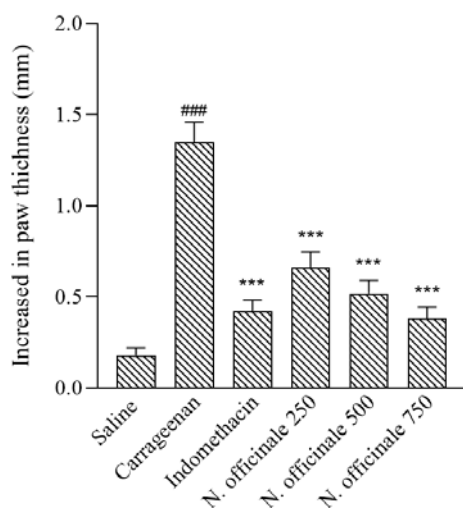


Fig. 1. Effect of ethanol extract of *Nasturtium officinale* on carrageenan-induced paw edema in rats. The extract (250, 500, and 750 mg/kg, p.o.), and indomethacin (10 mg/kg, p.o.) were administrated 45 min prior to carrageenan (1%) injection. The paw thickness was evaluated 4 h after carrageenan injection and the values represent the mean \pm SEM increased in the paw thickness, $n = 6$. ### $P < 0.001$ Indicates significant difference compared to the saline group and *** $P < 0.001$ versus carrageenan group.

inflammation 4 h after carrageenan injection. Pretreatment with indomethacin (10 mg/kg) and the plant extract (250, 500, and 750 mg/kg) 45 min before carrageenan injection significantly reduced the paw inflammation.

Formaldehyde induced arthritis in rats

Our results showed that the sub plantar injection of formalin in the hind paw of animals on the first and third days of the test caused a significant inflammation on days 1, 2, 3, 4, 5, 6, and 7. Oral treatment with the *N. officinale* ethanolic extract (500 mg/kg/day) considerably reserved the growth of formalin-induced paw swelling on days 1, 2, 3, 4, 5, 6, and 7 compared with the arthritic group. Indomethacin (10 mg/kg)-treated arthritic group also showed a significant reduction in the paw edema on days 1, 2, 3, 4, 5, 6, and 7 compared to the arthritic group (Fig. 2).

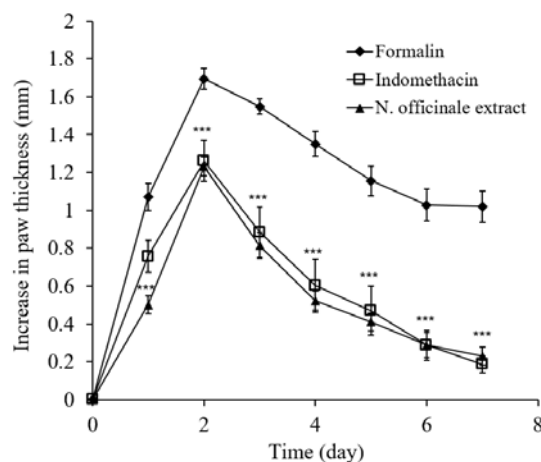


Fig. 2. Effect of ethanol extract of *Nasturtium officinale* on formalin-induced paw edema in rats. The extract (500 mg/kg, p.o.), and indomethacin (10 mg/kg, p.o.) were administrated 45 min prior to formalin (2%) injection and the paw thickness was evaluated for 7 consecutive days. The values represent the mean increase in the paw thickness \pm S.E.M ($n = 6$). *** $P < 0.001$ indicates significant differences compared to the formalin group.

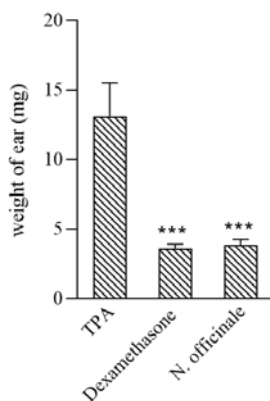


Fig. 3. Effect of topical administration of the ethanol extract of *Nasturtium officinale* on chronic inflammation induced by TPA in mice (2.5 μ g/ear \times 5 times). The extract (5 mg/ear), dexamethasone (0.5 mg/ear), and acetone were administered immediately after TPA application and 6 h later for 9 days. The values represent the mean variation in the ear weight \pm S.E.M (n = 6). *** P < 0.001 indicates significant differences compared to the TPA group. TPA, 12-O-tetradecanoyl phorbol 13-acetate.

TPA-induced chronic skin inflammation

The multiple topical administration of TPA (2.5 μ g/ear, 5 times) induced a prominent inflammation in the ear of mice compared with the untreated ear. Topical treatment with both dexamethasone (0.5 mg/ear) and the extract of *N. officinale* (5 mg/ear) for 9 consecutive days exhibited a significant improvement in the TPA-induced chronic ear inflammation when compared to untreated mice (Fig. 3).

Measurement of IL-1 β levels in the carrageenan treated paw

Carrageenan injection caused a marked elevation in IL-1 β level compared to those found after saline injection. Pretreatment with *N. officinale* extracts at either dose (250, 500, and 750 mg/kg) preserved the production of IL-1 β due to carrageenan challenges. Indomethacin (10 mg/kg, p.o.) also decreased the IL-1 β concentration compared with the carrageenan group (Fig. 4).

Measurement of TNF- α levels in the carrageenan-treated paw

The acute inflammation by injection of carrageenan (Fig 5) induced a marked elevation in the TNF- α levels compared with those observed after injection of saline. Pretreatment

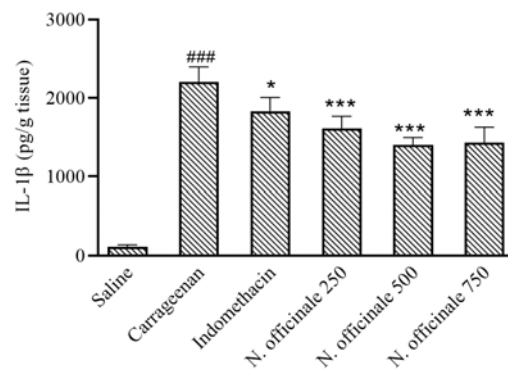


Fig. 4. Effect of *Nasturtium officinale* extracts on IL-1 β levels in the carrageenan-injected paws. Animals received the extract of *N. officinale* (250, 500, and 750 mg/kg, p.o.) and indomethacin (10 mg/kg) 45 min prior to subplantar injection of carrageenan. Four h after carrageenan injection, the paw was homogenized and IL-1 β levels in the supernatant were determined by ELISA. Data is expressed as mean \pm SEM of five to six rats. * P < 0.05, and *** P < 0.001 indicate significant differences compared to the carrageenan-treated group and ### P < 0.001 versus saline group. IL-1 β , Interleukin-1 beta.

with *N. officinale* extract at either dose (250, 500, and 750 mg/kg) did not inhibit the increase in the TNF- α levels owing to carrageenan injection (P > 0.05). Oral feeding with indomethacin (10 mg/kg) also did not display suppressive activity on the generation of the TNF- α due to the carrageenan challenge (P > 0.05).

Pathological evaluation

Histological examination of the paw specimens showed that the hind paw injection of formalin on the first and third days of excrement caused epidermal hyperplasia and significant penetration of lymphocytes and neutrophils with vascular congestion and edema. Oral treatment with the ethanolic extract of *N. officinale* (500 mg/kg) and indomethacin (10 mg/kg) decreased the mentioned signs of inflammation (Fig. 6).

Intensive and diffuse inflammatory lesions were observed in both the dermis and the epidermis of the treated ear after multiple administrations of TPA, compared to the intact ear. Neutrophils were the primary infiltrated cells in the dermis. The *N. officinale* extract (5 mg/ear) and dexamethasone (0.5 mg/ear) ameliorated the indicated inflammatory events compared with TPA-treated ear (Fig. 7).

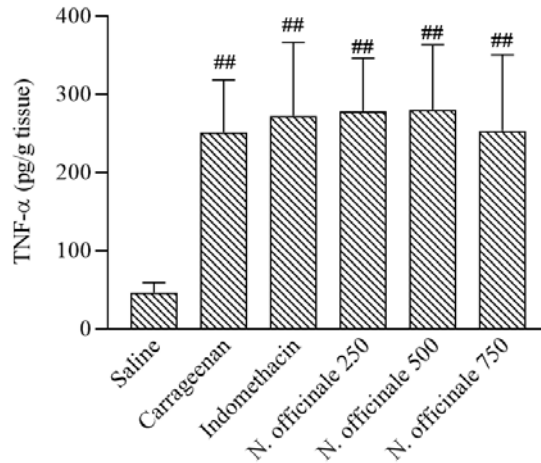


Fig. 5. Effect of *Nasturtium officinale* extracts on TNF- α levels in the carrageenan-injected paws. Animals received indicated doses of *N. officinale* (250, 500, and 750 mg/kg, p.o.) and indomethacin (10 mg/kg) 45 min prior to subplantar injection of carrageenan. Four h after subplantar injection of carrageenan, the paw was homogenized and TNF- α levels in the supernatant were determined by ELISA. Data are expressed as mean \pm SEM of five to six rats. ^{##} $P < 0.01$ Indicates significant differences compared to the saline-treated animals. TNF- α , Tumor necrosis factor.

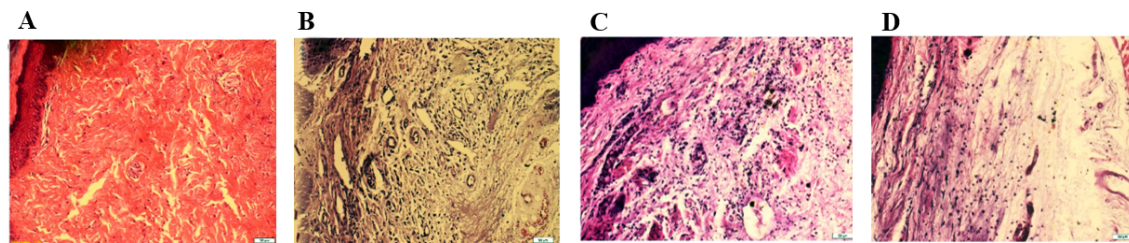


Fig. 6. Histopathological sections of rat paw after sub-plantar injection of formalin (7 days). (A) Normal paw; (B) formalin-treated rat paw, edema, and migration of leukocytes especially neutrophils in the paw tissues; (C) indomethacin (10 mg/kg, p.o.), reduced paw swelling and infiltration of neutrophils; and (D) *Nasturtium officinale* (500 mg/kg), decreased the formation of swelling and infiltration of neutrophils compared with the formalin-injected paw. Hematoxyline and eosin were used to stain the tissues sections, magnification $\times 20$.

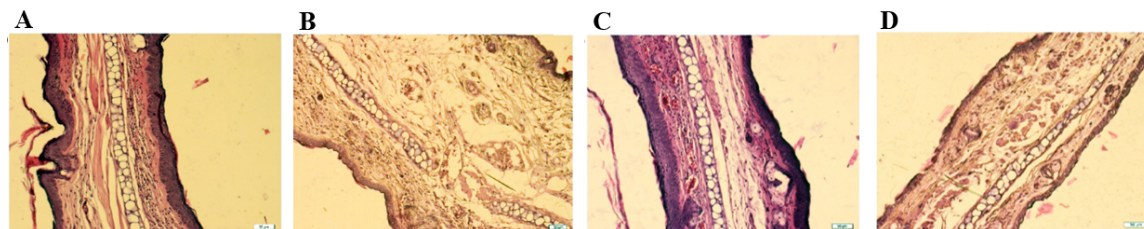


Fig. 7. Histopathological biopsies of mouse ear after multiple topical applications of TPA. (A) Normal ear; (B) TPA-treated ear, swelling, hyperalgesia, and infiltration of neutrophil; (C) dexamethasone (0.5 mg/ear), reduced edema and neutrophil infiltration; (D) *Nasturtium officinale* (5 mg/ear), inhibited the changes induced by TPA. Hematoxyline and eosin were used to stain the tissues sections, magnification $20\times$. TPA, 12-O-tetradecanoyl phorbol 13-acetate.

DISCUSSION

The present data showed that *N. officinale* extract displayed a noticeable anti-inflammatory activity against the two chronic inflammatory models including paw edema provoked by formalin in rats and skin edema induced by several topical administrations of TPA in mice. In traditional medicine of Iran and some countries, *N. officinale* is used topically or orally to alleviate the severity of rheumatoid arthritis (27). Therefore, we decided to use formaldehyde-induced arthritis in rats, which is similar to rheumatoid arthritis in humans, to show whether oral administration of *N. officinale* is effective in treating chronic inflammation.

It is well-established that the chronic inflammatory model of formalin is a suitable model for estimating antiproliferative properties and screening of anti-arthritis compounds (28). Formalin inflammation is often described as a biphasic event. The first phase is related to a rise in vascular permeability and discharge of bradykinin, while serotonin, bradykinin, histamine, and prostaglandin increase in the second phase (29). Our previous finding showed noticeable anti-inflammatory properties of *N. officinale* extract during both the first and second phases of formalin-induced swelling, probably by preventing the discharge of the indicated mediators (15). Chronic inflammation, a pathological state of inflammation, is an essential debilitating factor. Therefore, it was valuable to find whether the anti-inflammatory activities of *N. officinale* against acute inflammatory models could be extended to the chronic model as well. Thus, according to the pattern of formalin-induced chronic inflammation, a second dose of formalin was injected on the third day of the experiment. This model is often considered a chronic inflammatory reaction and used in chronic inflammatory experiments (30). Oral treatment with *N. officinale* extract (500 mg/kg) for 7 consecutive days considerably inhibited the development of inflammation in formalin-induced arthritis, which was similar to the effect observed with indomethacin. Histopathological findings confirmed these results. Therefore, it could be argued that *N. officinale* is a potential source of drugs against human arthritis.

As mentioned above, in the traditional medicine of some countries, this plant has been used topically in the control of rheumatoid arthritis (27). Therefore, it was tried to examine the effect of topical administration of the watercress extract against the TPA-induced chronic inflammation on the mice ear. A single topical administration of TPA on mice ears induces an acute inflammation that causes edema, erythema, and polymorph nuclear leukocyte infiltration. In contrast, the multiple application of TPA caused severe edema, epidermal hyperplasia, and further penetration of inflammatory cells (31). Lipoxygenase, cyclooxygenase, phospholipase A inhibitors, and glucocorticoids inhibit the TPA-induced acute inflammation, while the cyclooxygenase inhibitors did not suppress the TPA-induced chronic inflammation (32). TPA-induced skin cancer is strongly associated with inflammatory reactions such as the overexpression of cyclooxygenase-2 and inducible nitric oxide synthases proteins and the secretion of inflammatory cytokines (33). The NF- κ B signaling pathway has been established to involve in the mouse ear inflammation caused by TPA (34). Topical application of *N. officinale* extract for nine consecutive days was influential in reducing TPA-induced chronic inflammation. Our data are in good agreement with the findings of Camponogara *et al.* that reported that *N. officinale* significantly inhibited the croton oil-induced skin inflammation. They found that the anti-inflammatory effects of watercress, to some extent, were related to glucocorticoid receptors and NF- κ B pathways (18). Therefore, one possibility to explain the TPA results is that the extract's anti-inflammatory effects, to some extent, were related to interfering with glucocorticoid receptors and the NF- κ B pathways.

The topical anti-inflammatory activities of watercress proposed the existence of a lipophilic constituent in it that crosses the skin barrier and produces the anti-inflammatory influence (35). Pathological findings in chronic TPA-induced inflammation showed that the plant extract could prevent the development of inflammation by inhibiting neutrophil infiltration and reducing edema, similar to dexamethasone.

Carrageenan-evoked inflammation is usually used as a screening model to screen the potential anti-inflammatory properties of agents. Like the formalin test, the generation of TNF- α and IL-1 β has a significant role in carrageenan-induced inflammation (36). The result of the present study indicated that carrageenan injection induced a noticeable secretion of TNF- α and IL-1 β into the inflamed paws. These findings were consistent with earlier reported documents (37). Haj Hashemi *et al.* reported that the subplantar carrageenan injection stimulated the secretion of IL-1 β and TNF- α in the inflamed tissue (38). Here, the *N. officinale* extract inhibited the elevation in the levels of IL-1 β due to the carrageenan challenge. Other studies also reported that the anti-inflammatory and nephroprotective effects of *N. officinale* may be connected to its inhibitory effects on the secretion of proinflammatory cytokines (10).

It is important to notice that there is some evidence that reactive oxygen species are involved in physiological and pathological processes such as inflammation and aging (39). It has been reported that *N. officinale* showed significant antioxidant properties *in vitro* and *in vivo* conditions. Also, it has been well documented that phenolic and flavonoid agents have a vital role in scavenging free radicals (40). Our results indicated that the watercress *extract* has high phenol and flavonoid components. Therefore, it seems possible that some positive effects of *N. officinale* in decreasing inflammation were mediated through its antioxidant pathways.

At last not least, chlorogenic acid, caffeic acid, and rutin were identified in the crude extract of *N. officinale* (41). In this line, the anti-inflammatory activists of the three indicated components have been confirmed in the previous studies (42). Therefore, these phenolic components could have a central role in their anti-inflammatory effects.

CONCLUSION

Our findings indicated that topical and oral administration of *N. officinale* extracts produced a significant suppressive effect

against the two models of chronic inflammation in animals. These findings established the traditional use of this plant in managing chronic inflammatory conditions, such as rheumatoid arthritis. Also, they suggested that inhibition of the action/release of IL-1 β and reduction of neutrophils infiltration were involved in these effects. Additional research is necessary to verify the precise mechanism of action and characterize the active ingredients of *N. officinale*.

Acknowledgments

This study was financially supported by the Research Council of the Yasuj University of Medical Sciences, Yasuj, Iran through Grant No. 193.165. The authors appreciate the staff of the Research of Medicinal Plants Center of Yasuj University of Medical Sciences for their contributions to this project

Conflict of interest statement

The authors declared no conflict of interest in this study.

Authors' contribution

H. Sadeghi and H. Sadeghi contributed to the study concept and design, supervised the study, and drafted the manuscript; V. Zarezadeh, M. Mostafazadeh acquired the data; E. Panahi Kokhdan and H. Sadeghi analyzed and interpreted the data; M. Mostafazadeh and E. Panahi Kokhdan revised the manuscript critically for important intellectual content. The final version of the article was approved by all authors.

REFERENCES

1. Amaral S, Mira L, Nogueira JM, da Silva AP, Helena Florêncio M. Plant extracts with anti-inflammatory properties-a new approach for characterization of their bioactive compounds and establishment of structure-antioxidant activity relationships. *Bioorg Med Chem.* 2009;17(5):1876-1883. DOI: 10.1016/j.bmc.2009.01.045.
2. Manchali S, Murthy KNC, Patil BS. Crucial facts about health benefits of popular cruciferous vegetables. *J Funct Foods.* 2012;4(1):94-106. DOI: 10.1016/j.jff.2011.08.004.
3. Ozen T. Investigation of antioxidant properties of *Nasturtium officinale* (watercress) leaf extracts. *Acta Pol Pharm.* 2008;66(2):187-193. PMID: 19719054.

4. Bawa AS, Khanum F. Anti-inflammatory activity of *Rhodiola rosea*-"a second-generation adaptogen". *Phytother Res*. 2009;23(8):1099-1102. DOI: 10.1002/ptr.2749.
5. Sadeghi H, Azarmehr N, Razmkhah F, Sadeghi H, Danaei N, Omidifar N, *et al*. The hydroalcoholic extract of watercress attenuates protein oxidation, oxidative stress, and liver damage after bile duct ligation in rats. *J Cell Biochem*. 2019;120(9):14875-14884. DOI: 10.1002/jcb.28749.
6. Sedaghattalab M, Razazan M, Sadeghi H, Doustimotlagh AH, Toori MA, Abbasi Larki R, *et al*. Effects of *Nasturtium officinale* extract on antioxidant and biochemical parameters in hemodialysis patients: a randomized double-blind clinical trial. *Evid Based Complement Alternat Med*. 2021;2021:1632957,1-8. DOI: 10.1155/2021/1632957.
7. Qeini MH, Roghani M, Alagha A. The effect of *Nasturtium officinale* feeding on serum glucose and lipid levels and reorganization of beta cells in diabetic rats. *Razi J Med Sci*. 2010;17(73):53-61.
8. Alkofahi A, Atta AH. Pharmacological screening of the anti-ulcerogenic effects of some Jordanian medicinal plants in rats. *J Ethnopharmacol*. 1999;67(3):341-345. DOI: 10.1016/S0378-8741(98)00126-3.
9. Doustimotlagh AH, Kokhdan EP, Vakilpour H, Khalvati B, Barmak MJ, Sadeghi H, *et al*. Protective effect of *Nasturtium officinale* R. Br and quercetin against cyclophosphamide-induced hepatotoxicity in rats. *Mol Biol Rep*. 2020;47(7):5001-5012. DOI: 10.1007/s11033-020-05556-7.
10. Karami M, Mostafazadeh M, Sadeghi H, Sadeghi H, Mehraban F, Kokhdan EP, *et al*. Nephroprotective effect of *Nasturtium officinale* (watercress) ethanol extract and vitamin E on vancomycin-induced nephrotoxicity in rats. *Jundishapur J Nat Pharm Prod*. 2018;13(1):e67178,1-8. DOI: 10.5812/jjnpp.67178.
11. Giallourou NS, Rowland IR, Rothwell SD, Packham G, Commene DM, Swann JR. Metabolic targets of watercress and PEITC in MCF-7 and MCF-10A cells explain differential sensitisation responses to ionising radiation. *Eur J Nutr*. 2019;58(6):2377-2391. DOI: 10.1007/s00394-018-1789-8.
12. Ramezani S, Javadi I, Kokhdan EP, Omidifar N, Nikbakht J, Sadeghi H, *et al*. Protective and therapeutic effects of ethanolic extract of *Nasturtium officinale* (watercress) and vitamin E against bleomycin-induced pulmonary fibrosis in rats. *Res Pharm Sci*. 2021;16(1):94-102. DOI: 10.4103/1735-5362.305192.
13. Shahrokhi N, Hadad MK, Shabani M. Effects of aqueous extract of water cress on glucose and lipids plasma in streptozotocin induced diabetic rats. *Pak J Physiol*. 2009;5(2):6-10.
14. Akbari Bazm M, Khazaei M, Khazaei F, Naseri L. *Nasturtium officinale* L. hydroalcoholic extract improved oxymetholone-induced oxidative injury in mouse testis and sperm parameters. *Andrologia*. 2019;51(7):e13294. DOI: 10.1111/and.13294.
15. Sadeghi H, Mostafazadeh M, Sadeghi H, Naderian M, Barmak MJ, Talebianpoor MS, *et al*. *In vivo* anti-inflammatory properties of aerial parts of *Nasturtium officinale*. *Pharm Biol*. 2014;52(2):169-174. DOI: 10.3109/13880209.2013.821138.
16. Shi JH, Sun SC. Tumor necrosis factor receptor-associated factor regulation of nuclear factor κ B and mitogen-activated protein kinase pathways. *Front Immunol*. 2018;9:1849-1861. DOI: 10.3389/fimmu.2018.01849.
17. Rex J, Lutz A, Faletti LE, Albrecht U, Thomas M, Bode JG, *et al*. IL-1 β and TNF α differentially influence NF- κ B activity and FasL-induced apoptosis in primary murine hepatocytes during LPS-induced inflammation. *Front Physiol*. 2019;10:117-131. DOI: 10.3389/fphys.2019.00117.
18. Camponogara C, Silva CR, Brusco I, Piana M, Faccin H, de Carvalho LM, *et al*. *Nasturtium officinale* R. Br. effectively reduces the skin inflammation induced by croton oil *via* glucocorticoid receptor-dependent and NF- κ B pathways without causing toxicological effects in mice. *J Ethnopharmacol*. 2019;229:190-204. DOI: 10.1016/j.jep.2018.10.011.
19. Nili-Ahmadabadi A, Akbari Z, Ahmadimoghaddam D, Larki-Harchegani A. The role of ghrelin and tumor necrosis factor alpha in diazinon-induced dyslipidemia: insights into energy balance regulation. *Pestic Biochem Physiol*. 2019;157:138-142. DOI: 10.1016/j.pestbp.2019.03.013.
20. Dong Q, He D, Ni X, Zhou H, Yang H. Comparative study on phenolic compounds, triterpenoids, and antioxidant activity of *Ganoderma lucidum* affected by different drying methods. *J Food Meas Charact*. 2019;13(4):3198-3205. DOI: 10.1007/s11694-019-00242-0.
21. Golkar P, Taghizadeh M, Jalali SAH. Determination of phenolic compounds, antioxidant and anticancer activity of *Chrozophora tinctoria* accessions collected from different regions of Iran. *J Food Biochem*. 2019;43(11):e13036. DOI: 10.1111/jfbc.13036.
22. Sadeghi H, Parishani M, Akbartabar Touri M, Ghavamzadeh M, Jafari Barmak M, Zarezade V, *et al*. Pramipexole reduces inflammation in the experimental animal models of inflammation. *Immunopharmacol Immunotoxicol*. 2017;39(2):80-86. DOI: 10.1080/08923973.2017.1284230.
23. Hajhashemi V, Sadeghi H, Minaiyan M, Movahedian A, Talebi A. Effect of fluvoxamine on carrageenan-induced paw edema in rats evaluation of the action sites. *Iranian J Pharm Res*. 2011;10(3):611-618. PMID: 24250395.
24. Zarezade V, Sadeghi H, Kokhdan EP, Nikbakht J, Molavi M, Mostafazadeh M, *et al*. Effect of ethanolic extract of *Stachys pilifera* Benth on subacute experimental models of inflammation and some

- underlying mechanisms. *Res Pharm Sci.* 2021;16(5):516-527.
DOI: 10.4103/1735-5362.323918.
25. Stanley PL, Steiner S, Havens M, Tramosch KM. Mouse skin inflammation induced by multiple topical applications of 12-*O*-tetradecanoylphorbol-13-acetate. *Skin Pharmacol.* 1991;4(4):262-271.
DOI: 10.1159/000210960.
 26. Sadeghi H, Hajhashemi V, Minaiyan M, Movahedian A, Talebi A. Further studies on anti-inflammatory activity of maprotiline in carrageenan-induced paw edema in rat. *Int Immunopharmacol.* 2013;15(3):505-510.
DOI: 10.1016/j.intimp.2013.01.018.
 27. Shahani S, Behzadfar F, Jahani D, Ghasemi M, Shaki F. Antioxidant and anti-inflammatory effects of *Nasturtium officinale* involved in attenuation of gentamicin-induced nephrotoxicity. *Toxicol Mech Methods.* 2017;27(2):107-114.
DOI: 10.1080/15376516.2016.1258748.
 28. Arzi A, Olapour S, Yaghooti H, Karampour NS. Effect of royal jelly on formalin induced-inflammation in rat hind paw. *Jundishapur J Nat Pharm Prod.* 2015;10(1):e22466.
DOI: 10.17795/jjnpp-22466.
 29. Sreejamole KL, Radhakrishnan CK, Padikkala J. Anti-inflammatory activities of aqueous/ethanol and methanol extracts of *Perna viridis* Linn. in mice. *Inflammopharmacology.* 2011;19(6):335-341.
DOI: 10.1007/s10787-010-0075-z.
 30. Banerjee S, Sur TK, Mandal S, Das PC, Sikdar S. Assessment of the anti-inflammatory effects of *Swertia chirata* in acute and chronic experimental models in male albino rats. *Indian J Pharmacol.* 2000;32(1):21-24.
 31. Liu J, Huang H, Huang Z, Ma Y, Zhang L, He Y, et al. Eriocitrin in combination with resveratrol ameliorates LPS-induced inflammation in RAW264.7 cells and relieves TPA-induced mouse ear edema. *J Funct Foods.* 2019;56:321-332.
DOI: 10.1016/j.jff.2019.03.008.
 32. Giner-Larza EM, Mañez S, Recio MC, Giner RM, Prieto JM, Cerda-Nicolas M, et al. Oleanonic acid, a 3-oxotriterpene from *Pistacia*, inhibits leukotriene synthesis and has anti-inflammatory activity. *Eur J Pharmacol.* 2001;428(1):137-143.
DOI: 10.1016/S0014-2999(01)01290-0.
 33. Wu JY, Chen YJ, Bai L, Liu YX, Fu XQ, Zhu PL, et al. Chrysoeriol ameliorates TPA-induced acute skin inflammation in mice and inhibits NF-κB and STAT3 pathways. *Phytomedicine.* 2020;68:153173.
DOI: 10.1016/j.phymed.2020.153173.
 34. Seo HJ, Park KK, Han SS, Chung WY, Son MW, Kim WB, et al. Inhibitory effects of the standardized extract (DA-9601) of *Artemisia asiatica* Nakai on phorbol ester-induced ornithine decarboxylase activity, papilloma formation, cyclooxygenase-2 expression, inducible nitric oxide synthase expression and nuclear transcription factor κB activation in mouse skin. *Int J Cancer.* 2002;100(4):456-462.
DOI: 10.1002/ijc.10489.
 35. Asuzu IU, Sosa S, Della Loggia R. The antiinflammatory activity of *Icacina trichantha* tuber. *Phytomedicine.* 1999;6(4):267-272.
DOI: 10.1016/S0944-7113(99)80019-1.
 36. Halici Z, Dengiz GO, Odabasoglu F, Suleyman H, Cadirci E, Halici M. Amiodarone has anti-inflammatory and anti-oxidative properties: an experimental study in rats with carrageenan-induced paw edema. *Eur J Pharmacol.* 2007;566(1-3):215-221.
DOI: 10.1016/j.ejphar.2007.03.046.
 37. Loram LC, Fuller A, Cartmell T, Mitchell B, Mitchell D. Behavioural, histological and cytokine responses during hyperalgesia induced by carrageenan injection in the rat tail. *Physiol Behav.* 2007;92(5):873-880.
DOI: 10.1016/j.physbeh.2007.06.015.
 38. Hajhashemi V, Sadeghi H, Minaiyan M, Movahedian A, Talebi A. The role of central mechanisms in the anti-inflammatory effect of amitriptyline on carrageenan-induced paw edema in rats. *Clinics.* 2010;65(11):1183-1187.
DOI: 10.1590/S1807-59322010001100022.
 39. Checa J, Aran JM. Reactive oxygen species: drivers of physiological and pathological processes. *J Inflamm Res.* 2020;13:1057-1073.
DOI: 10.2147/JIR.S275595.
 40. Pourmorad F, Hosseinimehr SJ, Shahabimajid N. Antioxidant activity, phenol and flavonoid contents of some selected Iranian medicinal plants. *Afr J Biotechnol.* 2006;5(11):1142-1145.
 41. Boligon AA, Janovik V, Boligon AA, Pivetta CR, Pereira RP, Rocha JBTD, et al. HPLC analysis of polyphenolic compounds and antioxidant activity in *Nasturtium officinale*. *Int J Food Prop.* 2013;16(1):61-69.
DOI: 10.1080/10942912.2010.528111.
 42. Bouhlali EDT, Hmidani A, Bourkhis B, Khouya T, Ramchoun M, Filali-Zegzouti Y, et al. Phenolic profile and anti-inflammatory activity of four Moroccan date (*Phoenix dactylifera* L.) seed varieties. *Heliyon.* 2020;6(2):e03436,1-10.
DOI: 10.1016/j.heliyon.2020.e03436.