

## Anti-inflammatory effects of alosetron mediated through 5-HT<sub>3</sub> receptors on experimental colitis

Azadeh Motavallian<sup>1,2,\*</sup>, Mohsen Minaiyan<sup>3,4,\*</sup>, Mohammad Rabbani<sup>3,4</sup>, Parvin Mahzouni<sup>5</sup>, and Sasan Andalib<sup>6,7</sup>

<sup>1</sup>Department of Pharmacology and Toxicology, School of Pharmacy, Guilan University of Medical Sciences, Rasht, I.R. Iran.

<sup>2</sup>Rhino-sinus, Ear, and Skull base Diseases Research Center, Department of Otolaryngology and Head and Neck Surgery, Amiralmomenin Hospital, School of Medicine, Guilan University of Medical Sciences, Rasht, I.R. Iran.

<sup>3</sup>Department of Pharmacology and Toxicology, School of Pharmacy and Pharmaceutical Sciences, Isfahan University of Medical Sciences, Isfahan, I.R. Iran.

<sup>4</sup>Isfahan Pharmaceutical Sciences Research Center, School of Pharmacy and Pharmaceutical Sciences, Isfahan University of Medical Sciences, Isfahan, I.R. Iran.

<sup>5</sup>Department of Clinical Pathology, School of Medicine, Isfahan University of Medical Sciences, Isfahan, I.R. Iran.

<sup>6</sup>Neuroscience Research Center, Road Trauma Research Center, Department of Neurosurgery, Poursina Hospital, Guilan University of Medical Sciences, Rasht, I.R. Iran.

<sup>7</sup>Research Unit of Clinical Physiology and Nuclear Medicine, Department of Clinical Research, Faculty of Health Sciences, University of Southern Denmark, Odense, Denmark.

### Abstract

Development of new medicine with fewer deleterious effects and more efficacies for treatment of inflammatory bowel disease is needed. 5-Hydroxytryptamine 3 receptor (5-HT<sub>3</sub>R) antagonists have exhibited analgesic and anti-inflammatory features *in vitro* and *in vivo*. The present study was designed to evaluate the anti-inflammatory effect of alosetron, a 5-HT<sub>3</sub>R antagonist, on trinitrobenzenesulfonic acid (TNBS)-induced ulcerative colitis in rats. Two h subsequent to induce colitis (intracolonic instillation of TNBS, 50 mg/kg) in male Wistar rats, alosetron (1 mg/kg), dexamethasone (1 mg/kg), meta-chlorophenylbiguanide (mCPBG, a 5-HT<sub>3</sub>R agonist, 5 mg/kg), or alosetron + mCPBG were administrated intraperitoneally for 6 days. Animals were thereafter sacrificed and the efficacy of drugs was evaluated macroscopically, histologically, and biochemically (myeloperoxidase, tumor necrosis factor-alpha, interleukin-6, and interleukin-1 beta) on distal colon samples. Treatment with alosetron and dexamethasone improved macroscopic and microscopic colonic damages significantly and decreased myeloperoxidase activity and colonic levels of inflammatory cytokines. The profitable effects of alosetron were antagonized by concurrent administration of mCPBG. Our data provided evidence that the protective effects of alosetron on TNBS-induced colitis can be mediated by 5-HT<sub>3</sub>R.

**Keywords:** Alosetron; Inflammatory bowel disease; Colitis; 5-HT<sub>3</sub> receptor; TNBS.

### INTRODUCTION

Inflammatory bowel disease (IBD), comprising ulcerative colitis (UC) and Crohn's disease, is a chronic relapsing intestinal disorder that influence the patients' quality of life (1). In spite of the fact that immunologic mechanisms are said to serve a crucial role in IBD pathogenesis, the etiology is not well understood (2). Many investigations have illustrated that the pathogenesis of IBD is

multifactorial. In fact, genetic, immune, and environmental factors have important roles in IBD pathogenesis (1,2,3). Massive cellular infiltration and immune system abnormalities involving heightened number of CD4<sup>+</sup> T lymphocytes, mast cells, neutrophils, and eosinophils are observed in IBD (3).

\*Corresponding authors:

A. Motavallian, Tel: +98-1333486477, Fax: +98-1333486475

Email: Motavallian.azadeh@gmail.com

M. Minaiyan, Tel: +98-3137927088, Fax: +98-3136680011

Email: minaiyan@pharm.mui.ac.ir

#### Access this article online



Website: <http://rps.mui.ac.ir>

DOI: 10.4103/1735-5362.258489

These conditions cause clinical manifestations of IBD including inflammation, ulceration, edema, diarrhea with blood and/or mucus, fever, abdominal pain, and gastric dysmotility (3). To date, no effective cure has been developed for IBD and treatments mostly focus on inducing and maintaining remission (1,3).

Both types of IBD are treated by aminosalicylates and corticosteroids as conventional therapies (1). In addition, alternative therapies include biological response modifiers and immunosuppressive drugs (4). Despite the fact that these drugs can manage IBD successfully, they exert adverse effects which curtail their administration.

Hence, there is a pressing need for investigating new treatments with lower adverse effects (4).

Serotonin (5-hydroxytryptamine, 5-HT) has been demonstrated to be an essential gastrointestinal signaling molecule responsible to normal and pathologic intestinal functions such as motility, secretion, and visceral perception (5). Moreover, it is commonly found in the immune-inflammatory axis and exerts its impact upon mammalian immune response (6). Intestinal inflammation might initiate from a change in 5-HT producing enterochromaffin (EC) cells which augments 5-HT content related to the pattern of IBD (7). 5-HT<sub>3</sub> receptor (5-HT<sub>3</sub>R) is one of the most fully worked out 5-HT<sub>3</sub>R subtypes with respect to gastrointestinal function (5). 5-HT<sub>3</sub>R is expressed in immune cells including T lymphocytes (8). Activation and proliferation of T-cell is increased by 5-HT<sub>3</sub> receptors activation placed on these cells (8). 5-HT<sub>3</sub>R antagonists have been commonly used to abate chemotherapy-induced emesis (9). Moreover, recent investigations suggested new clinical indications for this category of medicines (10,11). 5-HT<sub>3</sub>R antagonists involving tropisetron and ondansetron, possessing anti-inflammatory property were shown by *in vivo* and *in vitro* studies (11,12). Alosetron, a 5-HT<sub>3</sub>R antagonist, has been used for treatment of diarrhea-dominant irritable bowel syndrome (D-IBS) (13). The role of 5-HT in IBS pathology has been well investigated, but its actual impact on IBD pathology and

probable beneficial effects of alosetron on IBD have not been identified yet. Alosetron is effective to provide symptom relief, such as reducing abdominal pain in D-IBS patients (13). In spite of clinical effectiveness of alosetron in reducing symptom of IBS and functional dyspepsia, it was withdrawn from the market temporarily because of probably rare increases in ischemic colitis. However, it was finally reintroduced into the United States market exclusively on a limited basis for women with severe D-IBS not responding to other therapies (14).

To date, no specific research has been carried out in probable anti-inflammatory effect of alosetron, as a 5-HT<sub>3</sub>R antagonist; nonetheless, Li *et al.* reported that this drug blocks increased 5-HT signaling-induced visceral hyperalgesia (15).

Animal models have shown to be appropriate for investigation of pathogenesis of IBD and effects of drugs on tissue injury. By way of illustration, TNBS-induced colitis has been proposed as a highly applicable model of induction of IBD. In addition, this model uses an immunologic hapten that gives rise to acute ulcerative inflammation leading to chronic inflammation of the distal colon (16).

The changes in EC cell numbers, 5-HT content, and augmentation of serotonin secretion were observed in UC (7). Additionally, in TNBS model of colitis, an enhancement in the amount of 5-HT and secretion resembling the pattern of UC was seen (17). Amongst the varieties of colitis induction models, TNBS model is able to mimic both acute and chronic colitis efficiently (18).

Previous studies demonstrated increased content of 5-HT in UC. Therefore, it can be inferred that there might be an association between intestinal inflammation and a change in 5-HT content (7).

On this account, alosetron as a 5-HT<sub>3</sub>R antagonist with anti-nociceptive property is likely to be effective in treatment of TNBS-induced colitis.

Therefore, current study set out to evaluate the anti-inflammatory effect of alosetron through 5-HT<sub>3</sub>R upon common colonic inflammatory markers.

## MATERIALS AND METHODS

### Animals

Male Wistar rats (250 ± 20 g, 12-week-old), bred in animal house of School of Pharmacy and Pharmaceutical Sciences, Isfahan University of Medical Sciences, Isfahan, I.R. Iran, were used in this study. Animals were kept in a controlled environment with a temperature of 22 ± 1 °C and a lighting program of 12/12-h light/dark cycles. They received standard pelleted chow along with having free access to tap water. All experimental protocols were approved by the Animal Care Committee of the Isfahan University of Medical Sciences, Isfahan, I.R. Iran.

### Materials

Dexamethasone, alosetron, and metachlorophenylbiguanide (mCPBG) were provided from Iran Hormone Pharmaceutical Co. (Tehran, I.R. Iran), Santa Cruz Biotechnology (Santa Cruz, CA, USA), and Sigma Chemical Company (St. Louis, MO, USA), respectively. TNBS, Hexadecyltrimethyl-ammonium bromide (HTAB), aprotinin A, bovine serum albumin, phenylmethylsulfonyl fluoride, benzethonium chloride, ethylene diamine tetra acetic acid (EDTA), and Tween<sup>®</sup> 20 were purchased from Sigma Chemical Company (St. Louis, MO, USA). Enzyme-linked immunosorbent assay (ELISA) kits (ALPCO, USA) were provided to quantify the amount of colonic rat tumor necrosis factor alpha (TNF- $\alpha$ ), interleukin beta (IL-1 $\beta$ ), and IL-6.

### Groups

Rats were randomly divided into six groups of 6 in each and following treatments were administered: (I) TNBS-control group, rats received normal saline (intraperitoneally, ip) 2 h subsequent to induction of colitis; (II) normal group, animals were administered normal saline intracolonicly instead of TNBS; (III) dexamethasone group, dexamethasone (1 mg/kg, ip) was given 2 h following induction of colitis (19); (IV) alosetron group, alosetron (1 mg/kg, ip) was given 2 h following induction of colitis (20); (V) mCPBG group, mCPBG (5 mg/kg, ip), was administered 2 h following induction of colitis (21); (VI) alosetron +

mCPBG group, alosetron and mCPBG were concurrently given (ip) 2 h following induction of colitis. All treatment continued daily for 6 days.

### Induction of colitis

Animals were fasted for 36 h with free access to water, prior to induction of colitis. Colitis was induced using method of Morris *et al.* (22) after ensuring their health. A light ether anesthesia was conducted and 0.25 mL of 10 mg TNBS in ethanol 50% v/v (50 mg/kg of TNBS) was intracolonicly administered through a long feeding tube inserted 8 cm proximal to the anus. Rats were thereafter maintained in a head down position for 2-3 minutes to prevent immediate anal leakage of the instillate and returned to their cages with free access to food and water. Normal group received enema of normal saline (0.25 mL).

### Assessment of body weight changes and diarrhea

Over the course of experiment, body weight was recorded daily for 6 days (before the administration of TNBS or saline and following the procedure). Body weight loss percentage was then measured. More to the point, using arbitrary criteria, the fecal output was scored daily for 6 days as follows: 1, formed stools; 2, loosed stools; and 3, diarrhea.

### Macroscopic evaluation

Using ether inhalation, animals were sacrificed on day 6. The abdomens were opened and appearance of colon was assessed. Thereafter, distal colon was dissected, opened by longitudinal incisions and gently washed in normal saline. Distal colon weight/length ratio (mg/cm) and wet weight (mg) (8 cm from the anus) were recorded for each sample. Macroscopic scoring of visible colonic damage, determination of ulcer area and percent of necrosis were performed according to our previously described method (23).

### Histopathological assessment

For microscopic evaluation, colon samples were fixed in formalin (10%) individually, and dehydrated, embedded in paraffin,

processed, cut into 4  $\mu\text{m}$  thick sections and stained by haematoxylin and eosin (H&E).

Total colitis index was then attained by summing 3 sub-scores (inflammation severity, inflammation extent, and crypt damage) on H&E-stained and coded sections using a changed validated scoring system according to our procedure previously explained (24). Histological scoring was done by a coworker pathologist in a blinded fashion.

#### ***Determination of colonic myeloperoxidase activity***

Myeloperoxidase (MPO) as a biochemical marker of neutrophil infiltration within colon tissue was measured using the modified method of Bradley (24,25). MPO activity was expressed in units/100 mg of wet tissue.

#### ***Measurement of pro-inflammatory cytokines in the rat colon***

Colon tissues were weighed, snap frozen on liquid nitrogen and kept at a temperature of  $-70\text{ }^{\circ}\text{C}$ . These samples were then homogenized in phosphate buffered saline (pH 7.4) and after centrifugation, the supernatant was used for the measurement of TNF- $\alpha$ , IL-1 $\beta$ , and IL-6 by ELISA assay according to the kit instruction (ALPCO, Keewaydin, USA), as described earlier (23). The results were expressed as pg/g wet tissue.

#### ***Statistical analysis***

Using the SPSS software (Version 17.0), data analysis was conducted.

Parametric data were analyzed using one-way analysis of variance (ANOVA) followed by Tukey as post hoc test. Non-parametric data were analyzed by Mann-Whitney U test. Results were expressed as mean  $\pm$  standard error of mean (SEM).  $P < 0.05$  was delineated as statistically significant.

## **RESULTS**

#### ***Effect of alosetron on rats' body weight and diarrheal status***

Rats treated with TNBS showed body weight loss after 6 days ( $P < 0.001$ ). Rats in alosetron and dexamethasone-treated group showed a significant body weight loss, in

comparison with normal group ( $P < 0.001$ ). However, percent of body weight loss in TNBS-control group was significantly higher than in these groups after 6 days ( $P$  values are shown in Table 1).

As shown in Fig. 1, over the experiment, diarrheal status in TNBS-treated rats was significantly higher than normal group ( $P < 0.01$ ).

Dexamethasone and alosetron-treated rats exhibited a significant decrease in the diarrhea index, in comparison with TNBS-control group ( $P < 0.05$ ), especially after the initial 2 days of treatment following the induction of colitis. More to the point, there was no significant difference in the daily diarrheal status between animals treated with alosetron and dexamethasone, over the experiment. mCPBG as a serotonin agonist could not alter the diarrheal status of TNBS-treated rat; however, it antagonized the beneficial effects of alosetron.

#### ***Effect of alosetron on macroscopic changes of colitis***

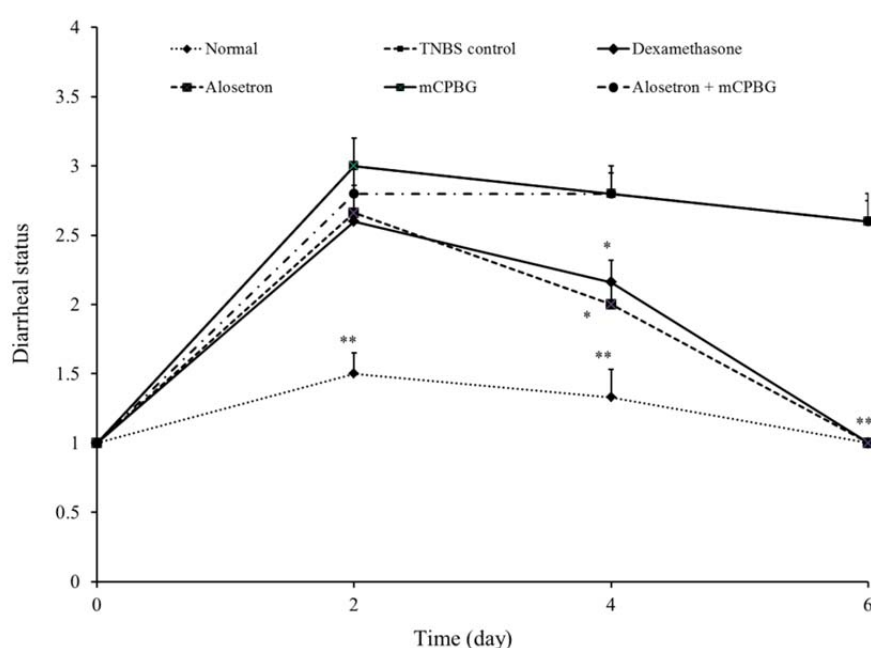
Normal group showed intact colonic mucosal appearance, while TNBS-control group experienced severe inflammation, hemorrhage, ulcer, necrosis, and thickened colon wall 6 days after induction of colitis (Table 1). Alosetron or dexamethasone-treated rats exhibited a significant decrease in ulcer severity and weight/length ratio, in comparison with TNBS-control group ( $P < 0.01$ ). Alosetron-treated group showed no significant difference in aforementioned variables, compared with the dexamethasone-treated rats. Moreover, the animal treated with alosetron + mCPBG experienced a significant increase in ulcer severity and weight length ratio, compared with alosetron-treated group ( $P < 0.01$ ).

We observed that TNBS-control group showed the higher percentage points of necrosis and ulcer area in comparison with dexamethasone and alosetron groups. These macroscopic features were significantly higher in alosetron plus mCPBG-treated rats, than in alosetron-treated rats (ulcer area,  $P < 0.05$ ; percent of necrosis,  $P < 0.01$ ). mCPBG, itself, did not change macroscopic properties of colitis.

**Table 1.** Effect of alosetron (1 mg/kg, daily) on macroscopic and histopathological parameters of the colon 6 days after induction of colitis with TNBS (50 mg/kg). Data are presented as mean ± SEM; n =6. \* (*P* < 0.05) and \*\* (*P* < 0.01) indicate significant differences compared to TNBS-control group.

Groups	Colonic weight/length ratio (mg/cm)	Bodyweight loss after 6 days (%)	Ulcer severity (0-15)	Ulcer area (cm <sup>2</sup> )	Necrosis (%)	Total colitis index (0-10)
Normal	64.8 ± 2.3	-1.9 ± 0.6	0.0	0.0	0.0	0.0
TNBS-control	256.3 ± 9.5	7.7 ± 0.7	12.2 ± 0.6	6.2 ± 0.1	51.5 ± 2.8	9.9 ± 0.1
Alosetron (1 mg/kg, ip)	156.1 ± 21.2**	3.5 ± 0.6**	4.83 ± 0.6**	4.1 ± 0.5*	26.3 ± 2.1**	5.1 ± 0.6**
mCPBG (5 mg/kg, ip)	252.1 ± 8.2	8.1 ± 0.8	11.5 ± 0.6	6.1 ± 0.2	51.3 ± 3.2	9.7 ± 0.1
mCPBG + alosetron	245.9 ± 8.2	7.9 ± 0.6	11.5 ± 0.4	6.0 ± 0.3	48.8 ± 5.4	9.2 ± 0.1
Dexamethasone (1mg/kg, ip)	161.9 ± 25.9**	3.9 ± 0.3*	5.33 ± 1.4**	4.0 ± 0.7*	27.0 ± 7.9**	4.8 ± 0.8**

TNBS, 2, 4, 6-trinitrobenzenesulfonic acid; mCPG, meta-chlorophenylbiguanide.



**Fig. 1.** Changes in diarrheal status before (day 0) and during 6 days of treatment after induction of colitis (TNBS, 50 mg/kg) in rats. Values are means ± SEM (n = 6). Data are presented as mean ± SEM; \* (*P* < 0.05) and \*\* (*P* < 0.01) indicate significant differences compared to TNBS-control group. Stool consistency was checked daily in rats (1, formed stools; 2, loosed stools; and 3, diarrhea). TNBS, 2, 4, 6-trinitrobenzenesulfonic acid; mCPG, meta-chlorophenylbiguanide.

### Effect of alosetron on histopathological features

Histological evaluation of colon in normal group revealed normal architecture with intact epithelial surface (Fig. 2). Colonic samples in TNBS-control group showed severe and intense transmural inflammation and/or diffuse necrosis, inflammatory granulomas, and submucosal neutrophils infiltration.

Histopathological damages in alosetron and dexamethasone-treated groups were significantly lower than those in TNBS-treated

group. These treatments decreased total colitis index (inflammation severity, inflammation extent, and crypt damage) in inflamed colons (Table 1).

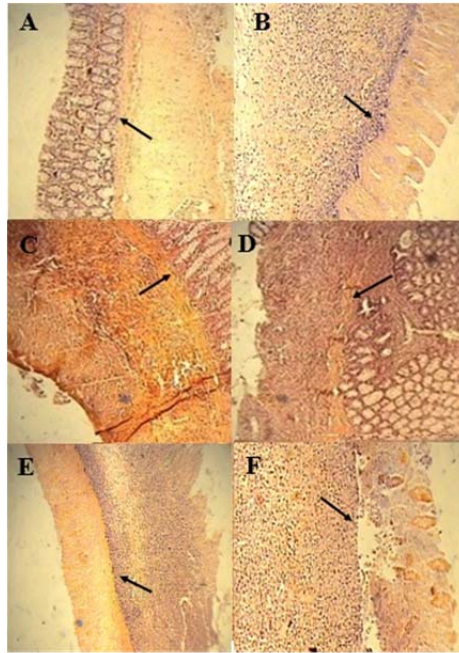
Furthermore, these groups showed regeneration of epithelium and reduced number of inflammatory cells in lamina propria. There was no significant difference between alosetron and dexamethasone-treated rats in this regard. Concurrent treatment of mCPBG and alosetron significantly exacerbated microscopic features, in

comparison with alosetron administration alone ( $P < 0.01$ ). There was no significant difference in histopathological aspects between mCPBG-treated and TNBS-control groups.

#### Effect of alosetron on myeloperoxidase activity

Table 2 shows that MPO activity increased considerably in the inflamed colons due to the intrarectal TNBS, compared to the normal-

treated rats. This confirmed the histological tests indicating high leucocyte infiltration in TNBS-control rats. Administration of alosetron or dexamethasone significantly declined the MPO activity level ( $P < 0.05$ ). mCPBG and alosetron concurrent administration heightened MPO activity, compared with alosetron alone ( $P < 0.05$ ). MPO activity failed to show a significant difference between the mCPBG and TNBS-control groups.



**Fig. 2.** Microscopic presentation of colon in TNBS-induced colitis in rats (hematoxylin and eosin staining; original magnification 10 $\times$ ). (A) Normal group, mucus layer and crypts are normal; (B) TNBS-control group, epithelial distortion, crypt damage, and inflammatory cell infiltrates; (C and D) dexamethasone and alosetron groups respectively, moderate mucosal and submucosal inflammation and mucosal inflammatory cell infiltrates; and (E and F), mCPBG and mCPBG + alosetrone, respectively, infiltration of neutrophils and destruction of mucosal architecture. TNBS, 2, 4, 6-trinitrobenzenesulfonic acid; mCPG, meta-chlorophenylbiguanide.

**Table 2.** Biochemical parameters of the rat's colon 6 days after induction of colitis with TNBS (50 mg/kg). Data are presented as mean  $\pm$  SEM; n = 6. \* ( $P < 0.05$ ) and \*\* ( $P < 0.01$ ) indicate significant differences compared to TNBS-control group.

Groups	MPO activity (Unit/100 mg wet tissue)	TNF- $\alpha$ (pg/g wet tissue)	IL-6 (pg/g wet tissue)	IL-1 $\beta$ (pg/g wet tissue)
Normal	0.6 $\pm$ 0.1	141 $\pm$ 13.8	3663.3 $\pm$ 240.2	1647.5 $\pm$ 452.4
TNBS-control	3.4 $\pm$ 0.4	249.9 $\pm$ 26.6	5210.3 $\pm$ 457.9	15296.0 $\pm$ 1579.7
Alosetron. (1 mg/kg, ip)	1.9 $\pm$ 0.3*	162.3 $\pm$ 12.1*	3776.0 $\pm$ 160.7*	8783.3 $\pm$ 1162.13**
mCPBG (5 mg/kg, ip)	3.5 $\pm$ 0.3	250.0 $\pm$ 23.1	5152.0 $\pm$ 385.3	15317.9 $\pm$ 1315.7
mCPBG + alosetron.	3.4 $\pm$ 0.4	247.6 $\pm$ 19.7	5243.3 $\pm$ 284.1	15646.8 $\pm$ 959.0
Dexamethasone.(1 mg/kg, ip)	1.9 $\pm$ 0.4*	160.6 $\pm$ 12.6*	3821.7 $\pm$ 270.7*	8641.2 $\pm$ 985.2**

TNBS, 2, 4, 6-trinitrobenzenesulfonic acid; mCPG, meta-chlorophenylbiguanide; MPO, myeloperoxidase; TNF, tumor necrosis factor; IL, interleukin.

**Effect of alosetron on cytokines profile**

Table 2 illustrates that TNF- $\alpha$ , IL-1 $\beta$ , and IL-6 raised dramatically in the TNBS-control rats, in contrast to the normal rats. These parameters were significantly lowered in alosetron/dexamethasone-treated rats. Rats undergoing alosetron and mCPBG treatment, experienced significantly high contents of the above-mentioned factors, compared to alosetron-treated rats (TNF- $\alpha$  and IL-6,  $P < 0.05$ ; IL-1 $\beta$ ,  $P < 0.01$ ). No significant difference was seen in TNF- $\alpha$ , IL-1 $\beta$ , and IL-6 levels between alosetron and dexamethasone groups. No significant changes in the levels of inflammatory cytokines demonstrated in the mCPBG rats, in comparison with TNBS-control rats.

**DISCUSSION**

Our findings indicated, for the first time, that alosetron mitigates TNBS-produced colitis in rats. Alosetron notably reduced colonic histological and macroscopic damages, pro-inflammatory cytokine levels and finally elevated tissue level of MPO. Furthermore, alosetron significantly treated colitis-associated diarrhea and body weight loss which was comparable with that of dexamethasone. Because these impacts were negated by concurrent administration of mCPBG and alosetron, the protection produced by alosetron can be explained by mediation of 5-HT<sub>3</sub> receptors. mCPBG rats experienced a colitis which was comparable to that of TNBS-control group. This can be due to severity of colitis reaching its peak approximately 6 days after induction of colitis and no more severity can be expected from mCPBG.

Several studies have investigated the probable mechanisms of 5-HT<sub>3</sub>R antagonist-induced ischemic colitis (26-28). Nevertheless, no plausible explanation has yet been proposed for occurrence of this pathologic condition. To date, it has remained unknown whether ischemic colitis directly arises from alosetron or it is due to an interaction with another medical condition (26). Compared with the small intestine, colon undergoes ischemia due to its low blood flow and small

microvasculature plexus (27). However, Grundy *et al.* showed that the chronic administration of alosetron (0.5 mg/kg, for 5 days, twice daily) did not alter baseline colonic blood flow significantly in rats (28). Despite the unchanged blood flow in the colon, a transient and minor constriction of the rat mesenteric vascular bed resulting from alosetron in rats was reported by Painsipp *et al.* (29). It is likely that alosetron and other 5-HT<sub>3</sub>R antagonists have mesenteric vasoconstriction effect. However, in previous study, the authors reported that mild colitis did not have a subtle relation to vasoconstrictor effect of 5-HT<sub>3</sub>R antagonism within the colon (29). Hence, this result rules out the assumption that inflammation (as seen also in UC) may have a risk for 5-HT<sub>3</sub>R ligands to cause splanchnic vasoconstriction and ischemic colitis (29). In the present study, we also selected a 6-day treatment regimen in which the colon blood flow remains unaltered.

Protease-activated receptor-2 (PAR-2) is a G-protein-coupled receptor. Activation of PAR-2 is involved in the nociceptive processing and neurogenic inflammation (15). PAR-2 has been found in the EC cells (15). Li *et al.* suggested that PAR-2 activation proliferates colon EC cell heightens synthesis of 5-HT, and thus brings about visceral hyperalgesia. Moreover, the authors reported that alosetron ameliorated the visceral hyperalgesia induced by PAR-2 agonist significantly (15). This suggests that activation of 5-HT<sub>3</sub>R contributes to the hypersensitivity induced by PAR-2 agonist (15). Hence, it can be inferred that alosetron is likely to be useful for relieving pain in UC.

In the current study, we found that the level of IL6, IL-1 $\beta$ , and TNF- $\alpha$  increased after TNBS instillation. Our findings suggested that the colonic profile of these mediators was reduced by alosetron. This probably results from inhibition of synthesis and/or release of these mediators.

MPO activity is an important index of neutrophil influx in inflamed tissues of intestine (25,30). We found that the ability of alosetron in decreasing neutrophil infiltration was due to suppressed MPO activity in colon. This inhibitory effect of alosetron correlates



with attenuation of microscopic and macroscopic injury scores. This might suggest its protective influence on colon injury.

Additionally, it is proposed that some helpful effects of alosetron upon rat colitis can be at least due to the ability in the blockage of 5-HT-induced inflammatory neuropeptide liberation (31,32). In spite of the fact that no *in vitro* or *in vivo* study investigated the probable anti-inflammatory effect of alosetron, other 5-HT<sub>3</sub>R antagonists such as tropisetron and ondansetron were demonstrated to possess anti-inflammatory properties. With these in mind, whether the alosetron similar to other 5-HT<sub>3</sub>R antagonist has anti-inflammatory effect is a question. If this hypothesis is confirmed, this property of alosetron also is likely to be involved in its salutary effects upon TNBS-induced colitis.

To draw a conclusion, this study suggests that alosetron, as a 5-HT<sub>3</sub>R antagonist, attenuated the severity of TNBS-induced colitis. Alosetron exerted a positive effect upon colonic injuries, neutrophil infiltration, and corresponding pro-inflammatory mediators. Additionally, the anti-nociceptive effect of alosetron on IBS has been well documented. Despite the fact that ischemic colitis is the most deleterious side effect of alosetron in IBS patients, its incidence is extremely low. In addition, if ischemic colitis occurred during the experiment, we would expect deterioration in histological and biochemical injuries of colitis. In this regard, further studies are required to establish whether ischemic colitis also occurs as a consequence of administration of alosetron in animal models of UC. Based on our findings, alosetron may find a place in the therapy of IBD in future, but complementary studies are recommended.

### CONCLUSION

Taken together, it is concluded that alosetron exerted anti-inflammatory effect on TNBS model of experimental colitis, despite the concerns about its ischemic colitis induction as a troublesome adverse effect and this activity was mediated through 5-HT<sub>3</sub> receptors. Hence, subsequent clinical

studies are required to evaluate its efficacy, safety, and suitability in human IBD conditions.

### ACKNOWLEDGMENTS

The research was financially supported (Grant No. 389362) by the Vice Chancellery of Research of Isfahan University of Medical Sciences, Isfahan, I.R. Iran.

### REFERENCES

1. Baumaqart DC, Sandborn WJ. Inflammatory bowel disease: clinical aspects and established and evolving therapies. *Lancet*. 2007;369(9573):1641-1657.
2. Kucharzik T, Maaser C, Lügering A, Kagnoff M, Mayer L, Targan S, *et al*. Recent understanding of IBD pathogenesis: implications for future therapies. *Inflamm Bowel Dis*. 2006;12(11):1068-1083.
3. Grisham MB. Molecular and cellular aspects of intestinal inflammation: clinical implications in inflammatory bowel disease. *Inflamm Bowel Dis*. 2000;1:1-14.
4. Braus NA, Elliott DE. Advances in the pathogenesis and treatment of IBD. *Clin Immunol*. 2009;132(1):1-9.
5. Hasler WL. Serotonin and the GI tract. *Curr Gastroenterol Rep*. 2009;11(5):383-391.
6. Idzko M, Panther E, Stratz C, Müller T, Bayer H, Zissel G, *et al*. The serotonergic receptors of human dendritic cells: identification and coupling to cytokine release. *J Immunol*. 2004;172(10):6011-6019.
7. Coates MD, Mahoney CR, Linden DR, Sampson JE, Chen J, Blaszyk H, *et al*. Molecular defects in mucosal serotonin content and decreased serotonin reuptake transporter in ulcerative colitis and irritable bowel syndrome. *Gastroenterology*. 2004;126(7):1657-1664.
8. Fiebich BL, Akundi RS, Seidel M, Geyer V, Haus U, Müller W, *et al*. Expression of 5-HT<sub>3A</sub> receptors in cells of the immune system. *Scand J Rheumatol Suppl*. 2004;119:9-11.
9. Kris MG. Ondansetron: a specific serotonin antagonist for the prevention of chemotherapy induced vomiting. *Important Adv Oncol*. 1994:165-177.
10. McCleane GJ, Suzuki R, Dickenson AH. Does a single intravenous injection of the 5HT<sub>3</sub> receptor antagonist ondansetron have an analgesic effect in neuropathic pain? A double-blinded, placebo-controlled cross-over study. *Anesth Analg*. 2003;97(5):1474-1478.
11. Müller W, Fiebich BL, Stratz T. New treatment options using 5-HT<sub>3</sub> receptor antagonists in rheumatic diseases. *Curr Top Med Chem*. 2006;6(18):2035-2042.



12. Fiebich BL, Akundi RS, Lieb K, Candelario-Jalil E, Gmeiner D, Haus U, et al. Antiinflammatory effects of 5-HT<sub>3</sub> receptor antagonists in lipopolysaccharide-stimulated primary human monocytes. *Scand J Rheumatol Suppl.* 2004;119:28-32.
13. Andresen V, Montori VM, Keller J, West CP, Layer P, Camilleri M. Effects of 5-hydroxytryptamine (serotonin) type 3 antagonists on symptom relief and constipation in nonconstipated irritable bowel syndrome: a systematic review and meta-analysis of randomized controlled trials. *Clin Gastroenterol Hepatol.* 2008;6(5):545-555.
14. Chang L, Chey WD, Harris L, Olden K, Surawicz C, Schoenfeld P. Incidence of ischemic colitis and serious complications of constipation among patients using alosetron: systematic review of clinical trials and post-marketing surveillance data. *Am J Gastroenterol.* 2006;101(5):1069-1079.
15. Li Z, Zhang X, Xu H, Sung JY, Bian ZX. Intracolonic administration of protease activated receptor-2 agonists produced visceral hyperalgesia by up-regulating serotonin in the colon of rats. *Eur J Pharmacol.* 2009;606(1-3):199-204.
16. Motavallian-Naeini A, Andalib S, Rabbani M, Mahzouni P, Afsharipour M, Minaiyan M. Validation and optimization of experimental colitis induction in rats using 2, 4, 6-trinitrobenzene sulfonic acid. *Res Pharm Sci.* 2012;7(3):159-169.
17. Linden DR, Chen JX, Gershon MD, Sharkey KA, Mawe GM. Serotonin availability is increased in mucosa of guinea pigs with TNBS-induced colitis. *Am J Physiol Gastrointest Liver Physiol.* 2003;285(1):G207-G216.
18. Ajuebor MN, Hogaboam CM, Kunkel SL, Proudfoot AE, Wallace JL. The chemokine RANTES is a crucial mediator of the progression from acute to chronic colitis in the rat. *J Immunol.* 2001;166(1):552-558.
19. Minaiyan M, Ghannadi AR, Etemad, Mahzouni P. A study of the effects of *Cydonia blonga* Miller (Quince) on TNBS-induced ulcerative colitis in rats. *Res Pharm Sci.* 2012;7(2):103-110.
20. Fornai M, Colucci R, Antonioli L, Ghisu N, Tuccori M, Gori G, et al. Effects of a bicarbonate-alkaline mineral water on digestive motility in experimental models of functional and inflammatory gastrointestinal disorders. *Methods Find Exp Clin Pharmacol.* 2008;30(4):261-269.
21. Callahan PM, Cunningham KA. Involvement of 5-HT<sub>2C</sub> receptors in mediating the discriminative stimulus properties of m-chlorophenylpiperazine (mCPP). *Eur J Pharmacol.* 1994;257(1-2):27-38.
22. Morris GP, Beck PL, Herridge MS, Depew WT, Szewczuk MR, Wallace JL. Hapten-induced model of chronic inflammation and ulceration in the rat colon. *Gastroenterology.* 1989;96(3):795-803.
23. Motavallian-Naeini A, Minaiyan M, Rabbani M, Mahzouni P. Anti-inflammatory effect of ondansetron through 5HT<sub>3</sub> receptors on TNBS-induced colitis in rat. *ECXLI J.* 2012;11:30-44.
24. Motavallian A, Minaiyan M, Rabbani M, Andalib S, Mahzouni P. Involvement of 5HT<sub>3</sub> receptors in anti-inflammatory effects of tropisetron on experimental TNBS-induced colitis in rat. *Bioimpacts.* 2013;3(4):169-176.
25. Bradley PP, Priebat DA, Christensen RD, Rothstein G. Measurement of cutaneous inflammation: estimation of neutrophil content with an enzyme marker. *J Invest Dermatol.* 1982;78(3):206-209.
26. Lewis JH. The risk of ischaemic colitis in irritable bowel syndrome patients treated with serotonergic therapies. *Drug Saf.* 2011;34(7):545-565.
27. Koutroubakis IE. Ischemic colitis: clinical practice in diagnosis and treatment. *World J Gastroenterol.* 2008;14(48):7302-7308.
28. Grundy D, Mclean P, Stead R. Impact of 5-HT<sub>3</sub> receptor blockade on colonic haemodynamic responses to ischaemia and reperfusion in the rat. *Neurogastroenterol Motil.* 2007;19(7):607-616.
29. Painsipp E, Shahbazian A, Holzer P. Alosetron, cilansetron and tegaserod modify mesenteric but not colonic blood flow in rats. *Br J Pharmacol.* 2009;158(5):1210-1226.
30. Motavallian A, Minaiyan M, Rabbani M, Mahzouni P, Andalib S, Abed A, et al. Does cisaperide, as a 5HT<sub>4</sub> receptor agonist, aggravate the severity of TNBS-induced colitis in rat? *Gastroenterol Res Prac.* 2012;2012. DOI: 10.1155/2012/362536.
31. Faerber L, Drechsler S, Ladenburger S, Gschaidmeier H, Fischer W. The neuronal 5-HT<sub>3</sub> receptor network after 20 years of research-evolving concepts in management of pain and inflammation. *Eur J Pharmacol.* 2007;560(1):1-8.
32. Hassani H, Lucas G, Rozell B, Ernfors P. Attenuation of acute experimental colitis by preventing NPY Y1 receptor signaling. *Am J Physiol Gastrointest Liver Physiol.* 2005;288(3):G550-G556.